

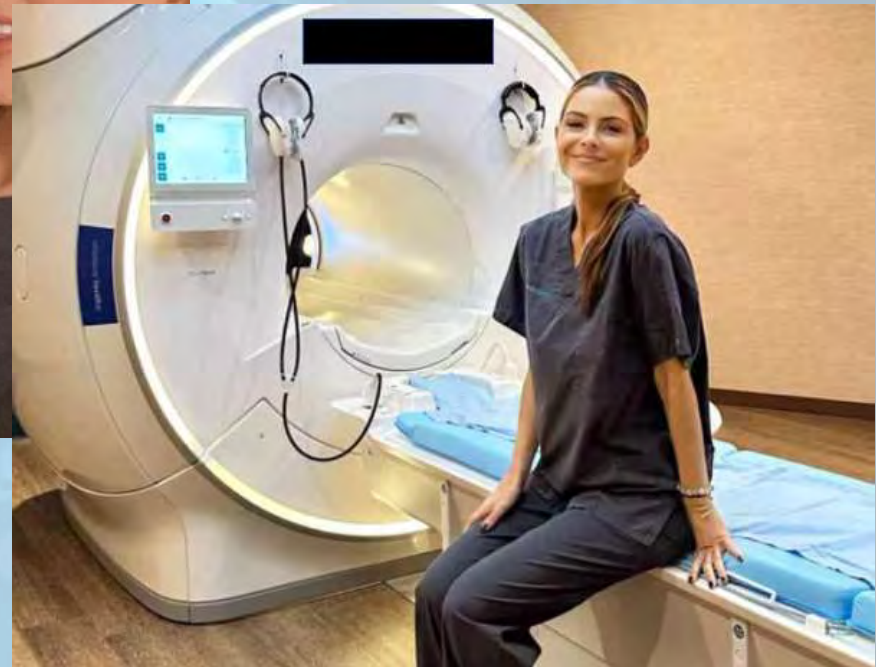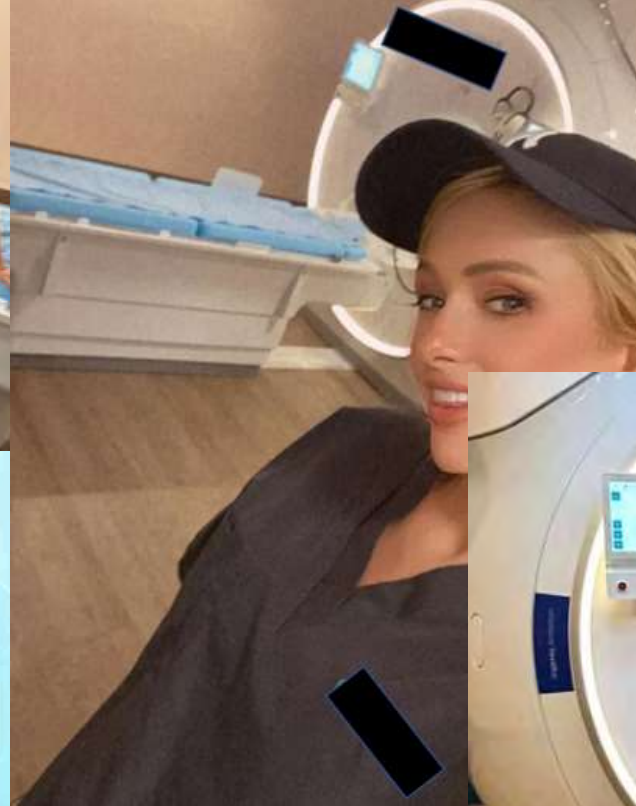


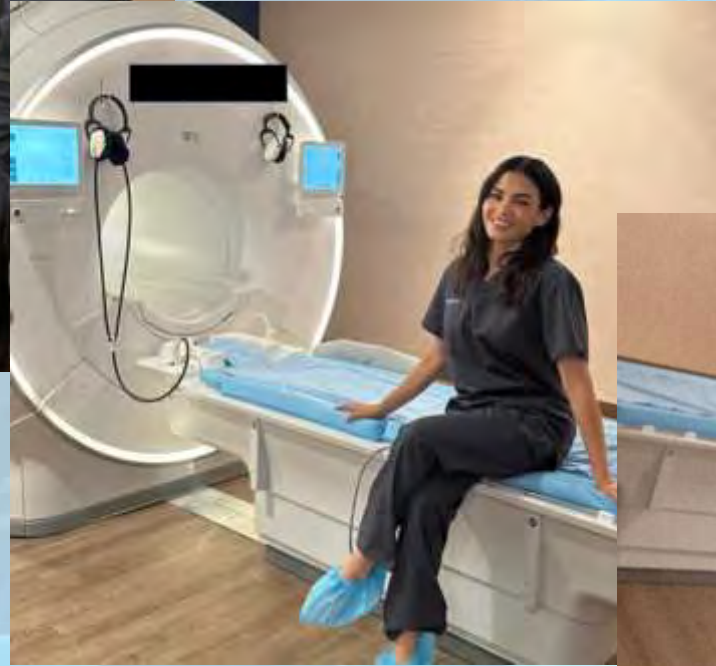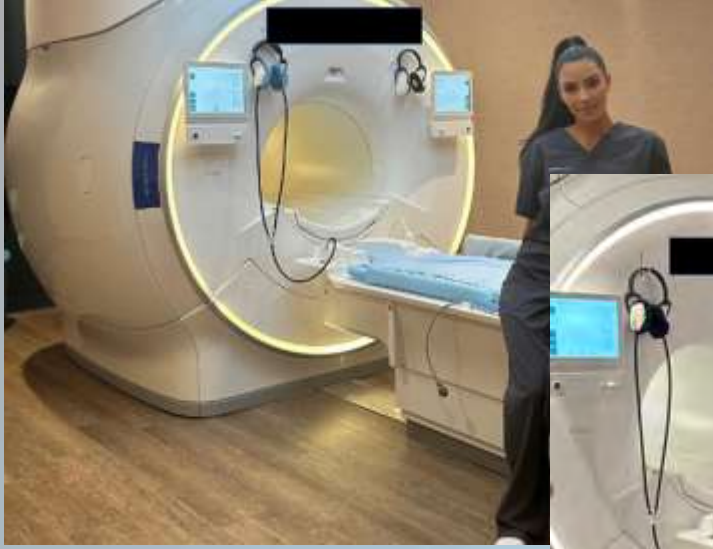**SCREENING WHOLE-BODY MRI
AND OTHER SCREENING IMAGING
EXAMS FOR CANCER DETECTION**

Lucy Muinov MD

Martin Goodenberger MD

UNMC Radiology



Kim?

Jenna?

Paris?

Maria?


HEALTH CARE

Kim Kardashian sparks debate on the benefits of full-body MRI scans



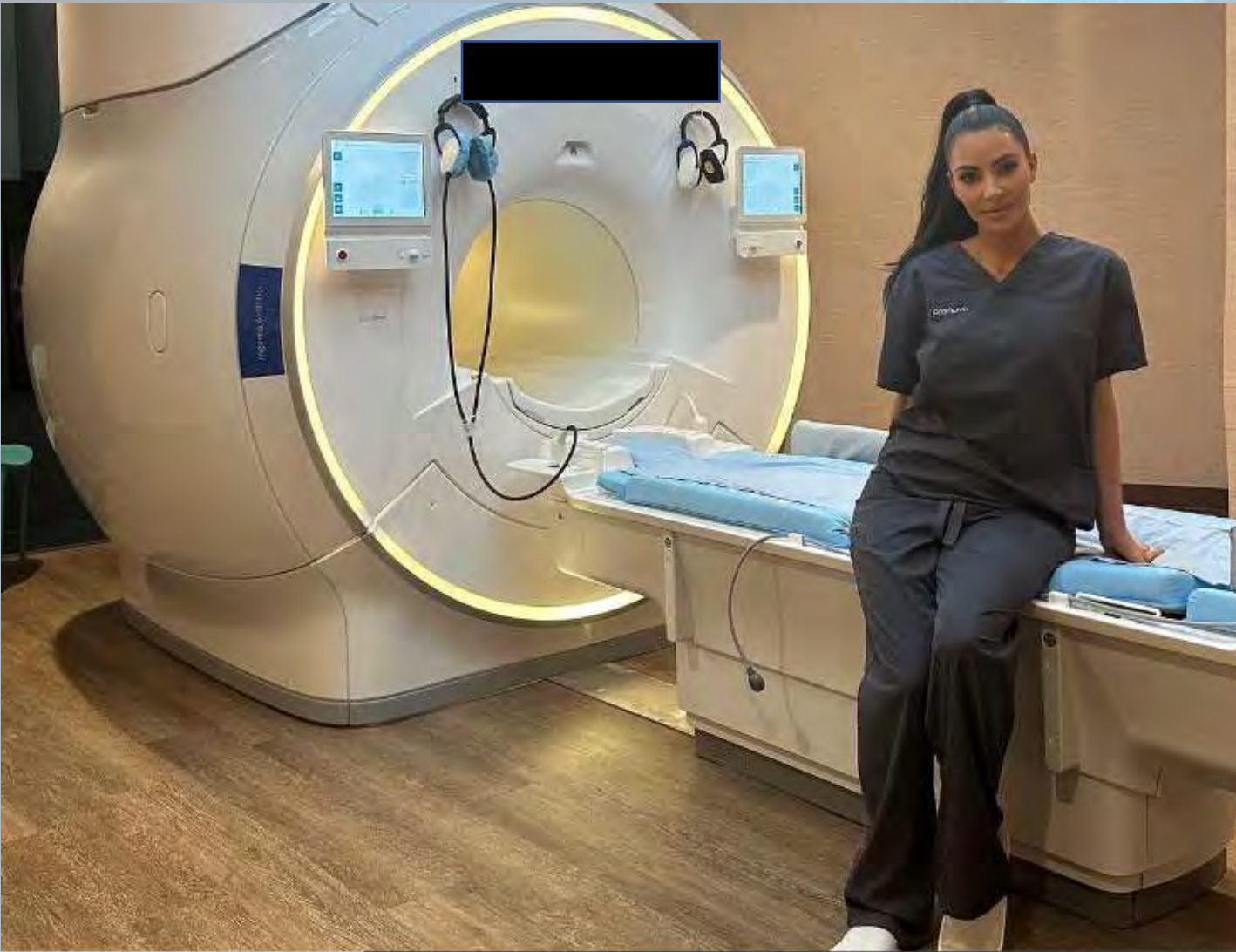By [Mohana Ravindranath](#) and [Lizzy Lawrence](#) Aug. 11, 2025

Reprints





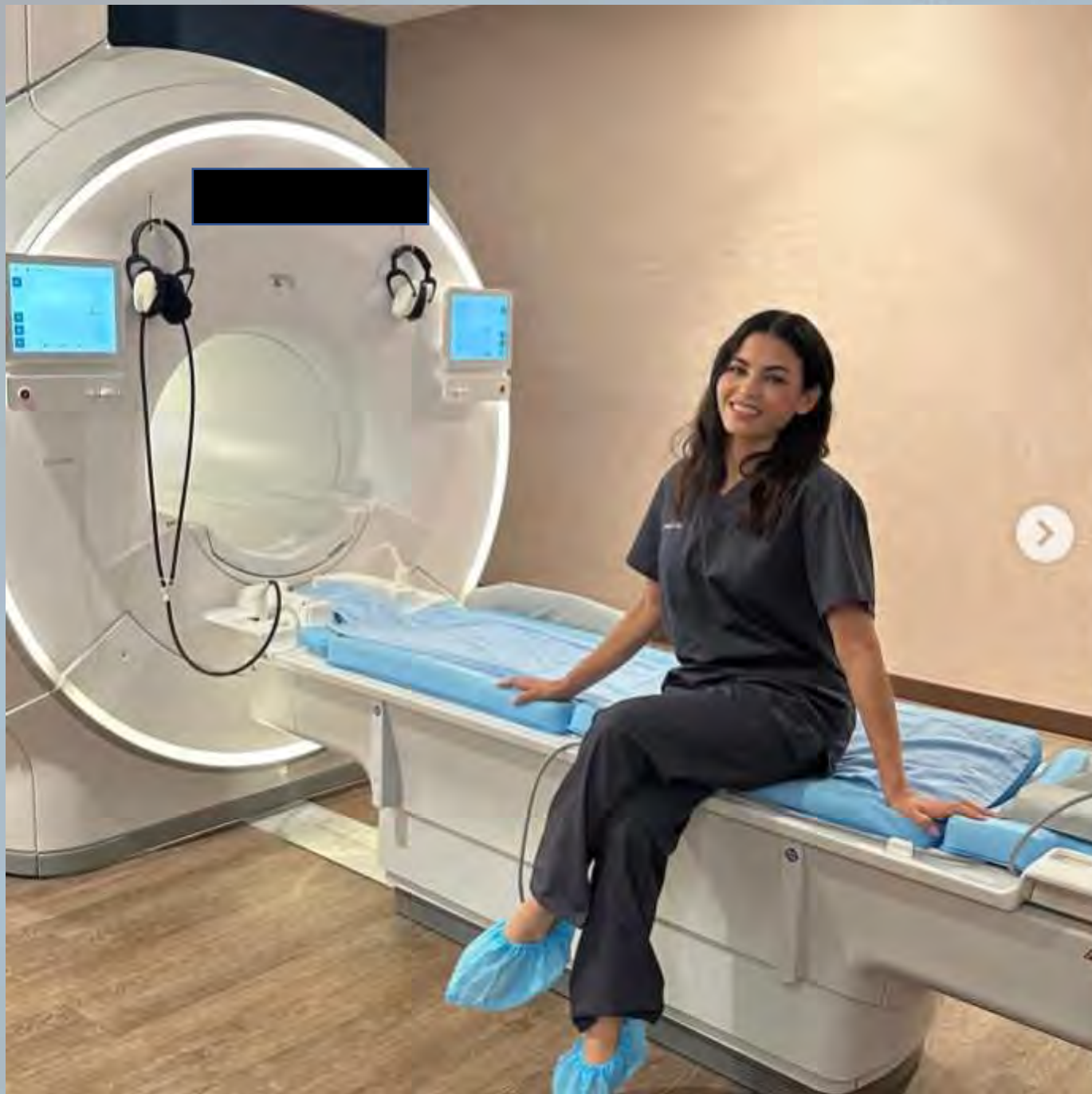Kim Kardashian Got a Full Body Scan, Why Medical Experts are Concerned





kimkardashian  Edited • 2w

I recently did this  scan and had to tell you all about this life saving machine.  full-body scan has the ability to detect cancer and diseases such as aneurysms in its earliest stages, before symptoms arise. It was like getting a MRI for an hour with no radiation. It has really saved some of my friends lives and I just wanted to share #NotAnAd.



Jennadewan Edited • 5w

Preventative medicine at its finest..

Last week I visited and got their full body MRI that specializes in early detection of cancer and more than 500 conditions! Their team had me feeling so relaxed.. they even play Netflix during your scan to help pass the time and calm nerves! I can't wait to get my results thank you 🙏❤️

I am so grateful to have been able to have this scan done and am all too aware that this is something that is currently out of reach for many with it being elective/ not covered by insurance. While this is all true... is working so hard to change that! Their mission is to democratize healthcare and change the current



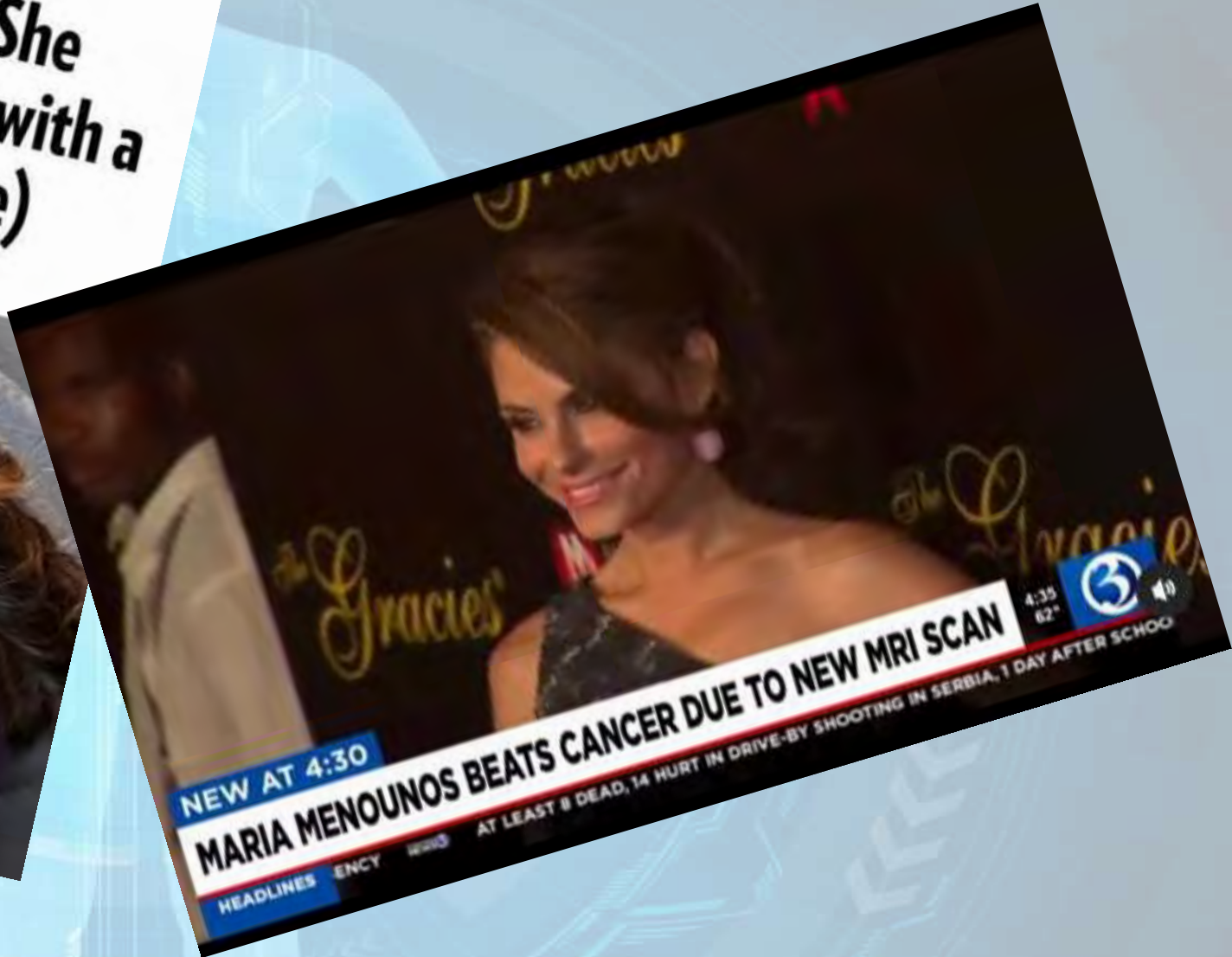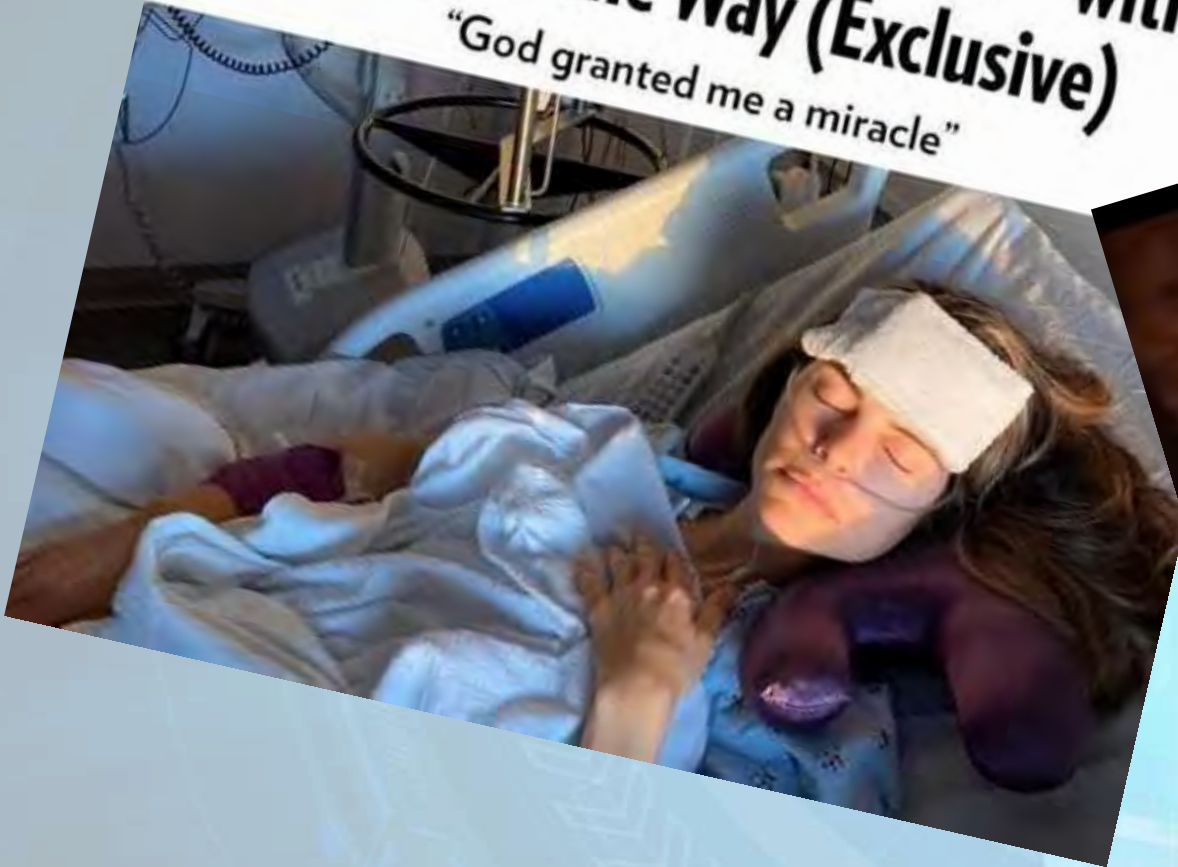56,602 likes

JUNE 14

People

Maria Menounos Reveals She Survived Pancreatic Cancer – with a Baby on the Way (Exclusive)

“God granted me a miracle”



CELEBRITIES

Maria Menounos

Add Topic +

Maria Menounos reveals she beat pancreatic cancer after early detection: 'So lucky'

**Morgan Hines**

USA TODAY

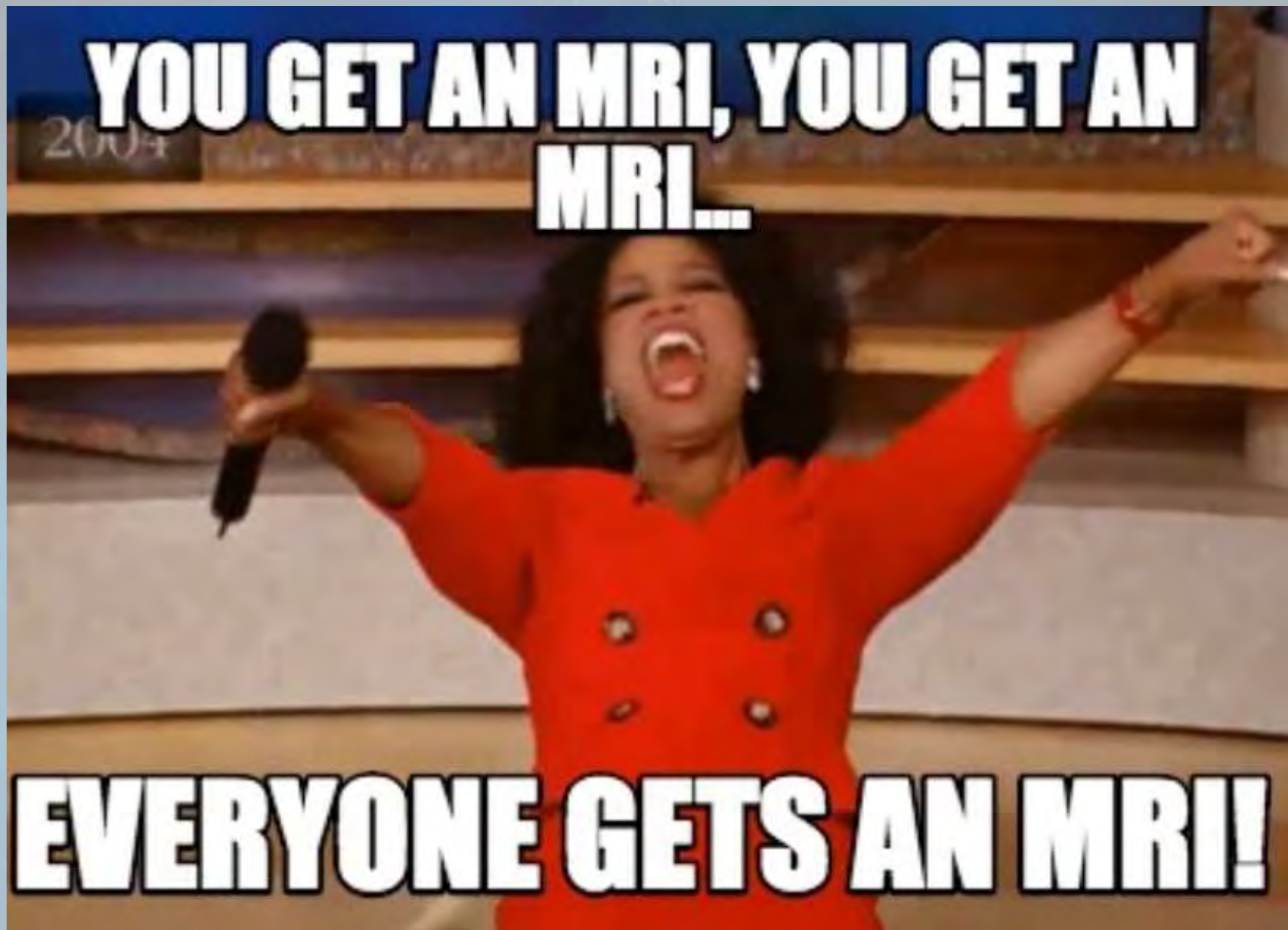Published 12:46 p.m. ET May 3, 2023 | Updated 3:17 p.m. ET May 8, 2023

"They said, 'Everything's fine.' But I kept having pains," she told People.

As her pain continued, she looked for answers and turned to a **full-body MRI scan** with a company called [REDACTED] which offers scans to the public for a fee. She said the scan found a 3.9 centimeter mass on her pancreas and a biopsy showed that the mass was a Stage 2 pancreatic neuroendocrine tumor, which was found to be cancerous.

**YOU GET AN MRI, YOU GET AN
MRI...**

EVERYONE GETS AN MRI!

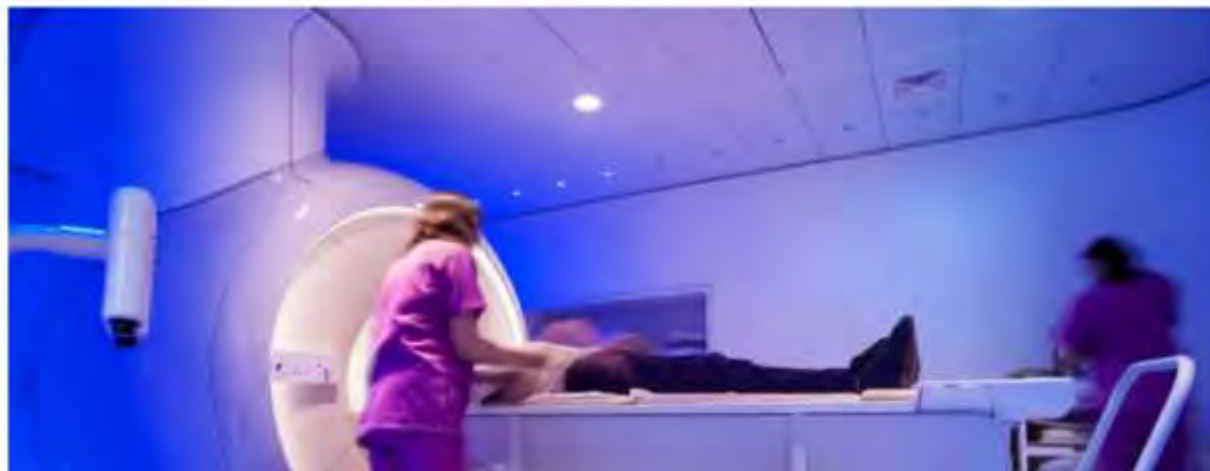

Full-Body MRI: What You Need to Know

BY ERIN POST — MAY 11, 2023

Share

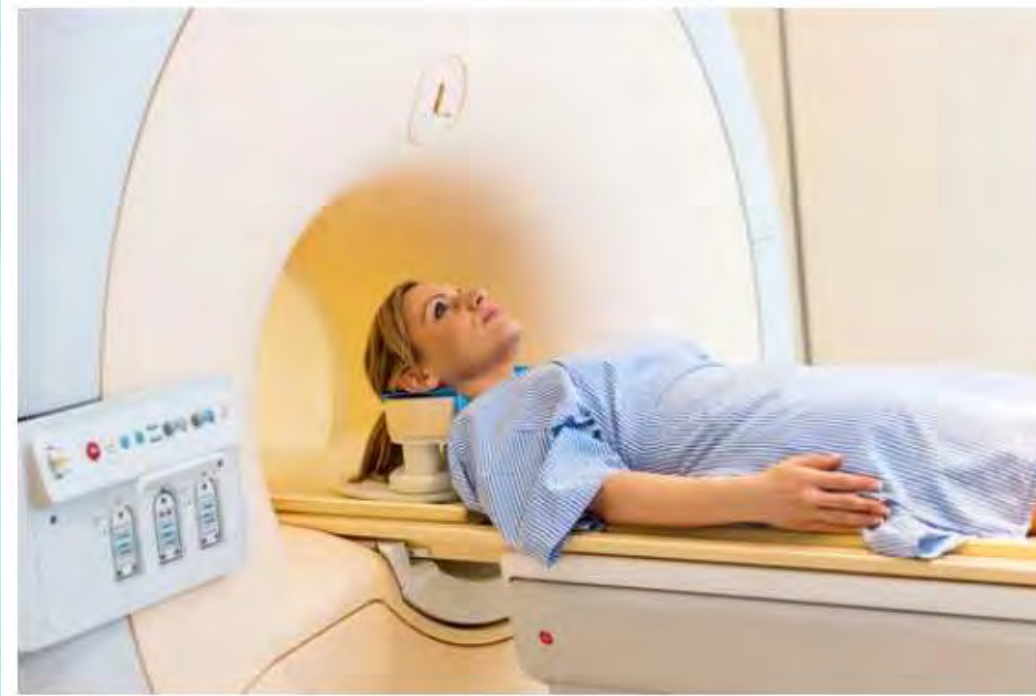Tweet



WebMD Health News

Do You Need A Full-Body MRI Scan? Probably Not, Experts Say

Written by Katie Camero





health

NEWS

CONDITIONS A - Z

NUTRITION

WELLNESS

WHAT TO BUY

ABC

Should You Get a Full-Body MRI? Radiologists Aren't Sure the Benefits Outweigh the Risks

By Julia Ries

Updated on August 9, 2023

SCREENING IMAGING EXAMS



- **WELL-ESTABLISHED:**
 - Mammography
 - Breast MRI
 - Low dose chest CT
 - Prostate MRI
 - CT colonography
- **UNDER INVESTIGATION**
 - Whole-body CT
 - Whole-body MRI
 - Whole-body PET/MRI
 - Others?

WHAT IS A WHOLE-BODY MRI?

- MRI of either entire body or areas at risk for cancer screening and detection
- Variable protocols
 - full body, head and torso, torso and extremities, etc
- Not universally available or recommended
- Becoming more available through private imaging centers for out-of-pocket fee
- Indicated in certain high-risk syndromes, predisposing for cancer development

ACR STATEMENT ON SCREENING TOTAL BODY MRI

April 17, 2023

ACR Statement on Screening Total Body MRI

[Share](#) [Recommend](#) [Bookmark](#)

The American College of Radiology® (ACR®), at this time **does not believe there is sufficient evidence to justify recommending total body screening** for patients with no clinical symptoms, risk factors or a family history suggesting underlying disease or serious injury.

To date, there is **no documented evidence that total body screening is cost-efficient or effective in prolonging life**. In addition, the ACR is concerned that such procedures will lead to the identification of **numerous non-specific findings that will not ultimately improve patients' health but will result in unnecessary follow-up testing and procedures, as well as significant expense.**

The ACR will continue to monitor scientific studies concerning the utility of screening total body MRI.

<https://www.acr.org/Media-Center/ACR-News-Releases/2023/ACR-Statement-on-Screening-Total-Body-MRI>

UNMC WHOLE-BODY SCREENING MRI: INDICATIONS

- **Li-Fraumeni Syndrome (LFS), P53 gene mutation**
 - High risk for sarcoma, breast, brain, adrenal, lung, GI, prostate cancer, melanoma, leukemia (field of view: shoulders to distal thighs)
 - Also need dedicated brain and breast MRIs
- **Rb (retinoblastoma) gene mutation**
 - High risk for retinoblastoma, cholangiocarcinoma, lung cancer, breast cancer, melanoma, urinary bladder, sarcoma (field of view: vertex to toes)
- **SDHx (succinate dehydrogenase) gene mutation**
 - Gastrointestinal cancers, GIST, paraganglioma, pheochromocytoma, renal cancer (field of view: skull base to pelvis)
- **UNMC Radiology does NOT offer screening whole-body MRIs for general population / average risk patients**

WHOLE-BODY "STIR" VS WHOLE-BODY MRI



- **Whole-Body STIR**

- Sensitive to edema and inflammation

- Indications:

- Myositis
- Weakness
- Myalgias
- Multiple myeloma
- Fever of unknown origin

- Read by MSK radiologists only

- **Whole-Body MRI**

- Indications

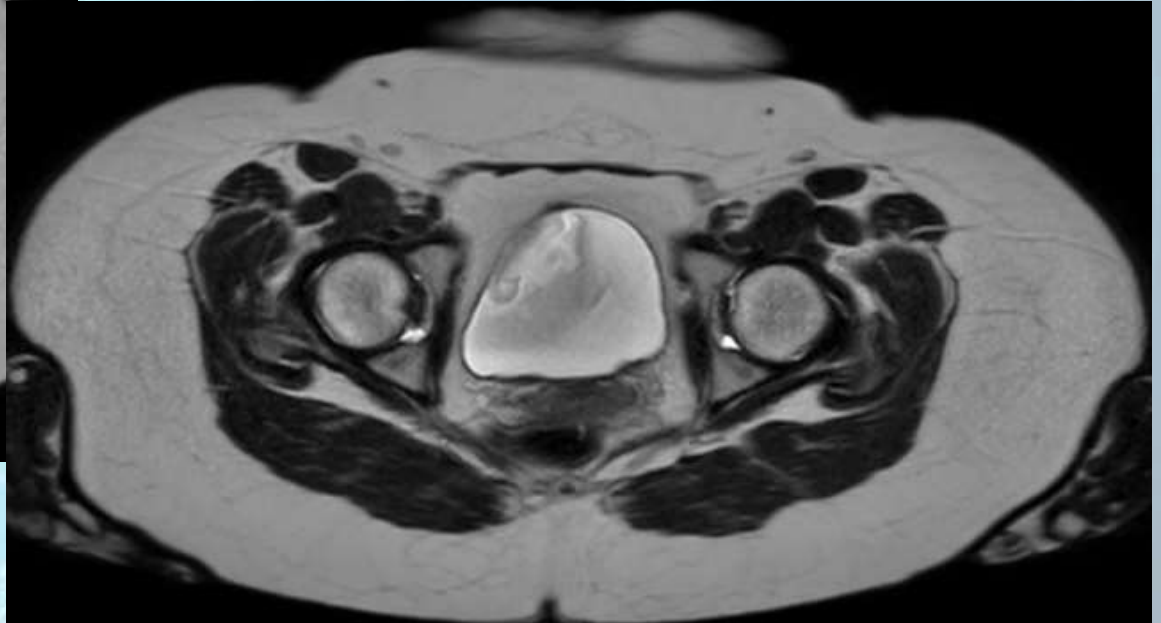
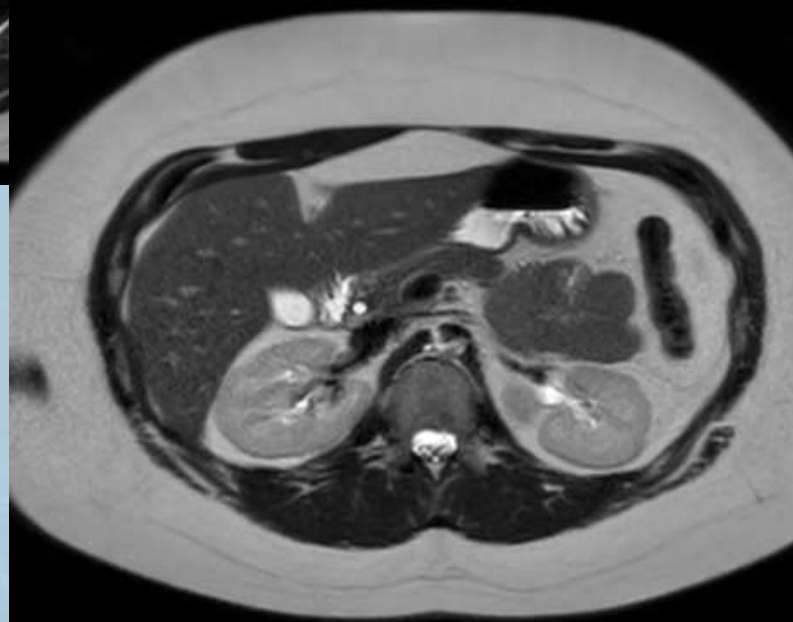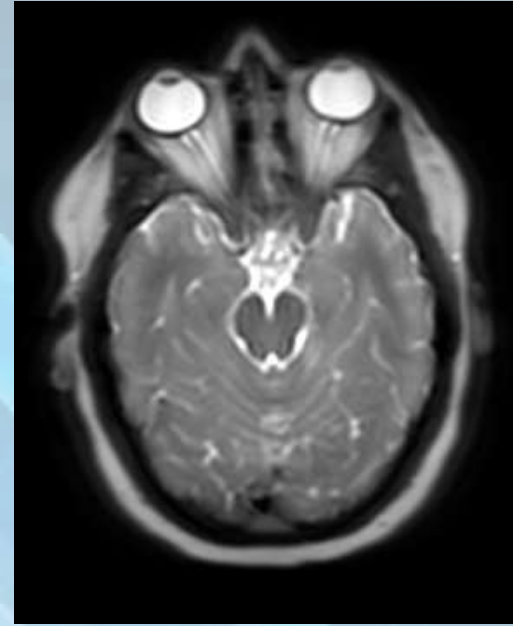
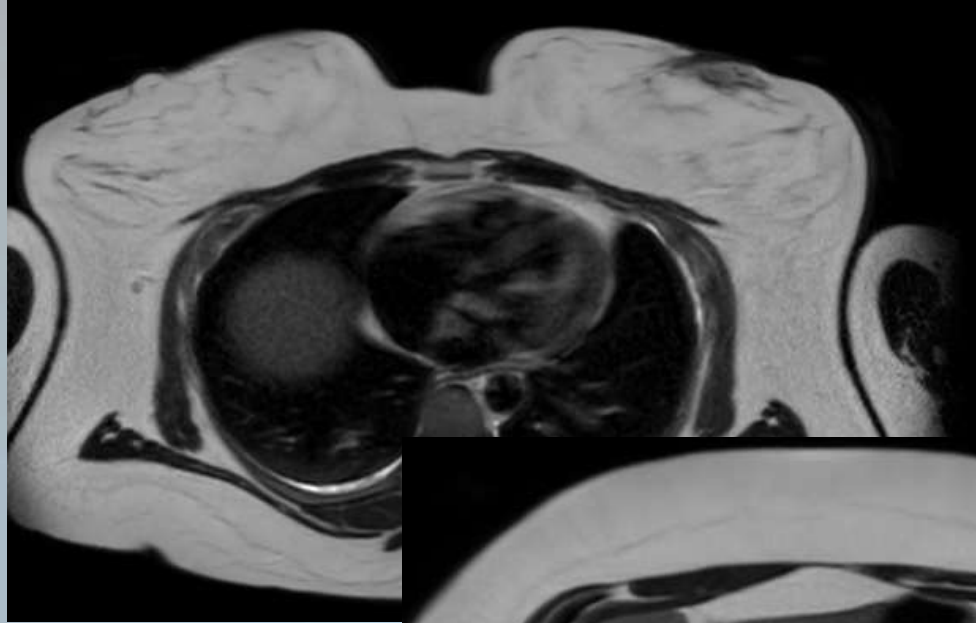
- Cancer predisposition syndromes

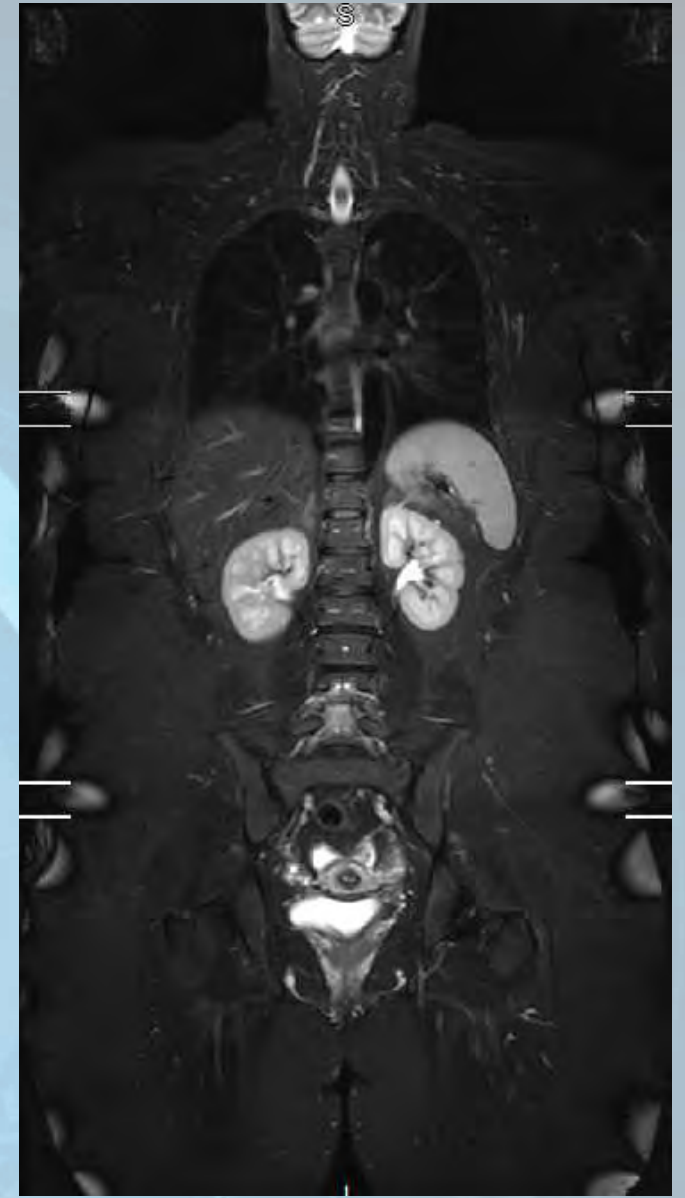
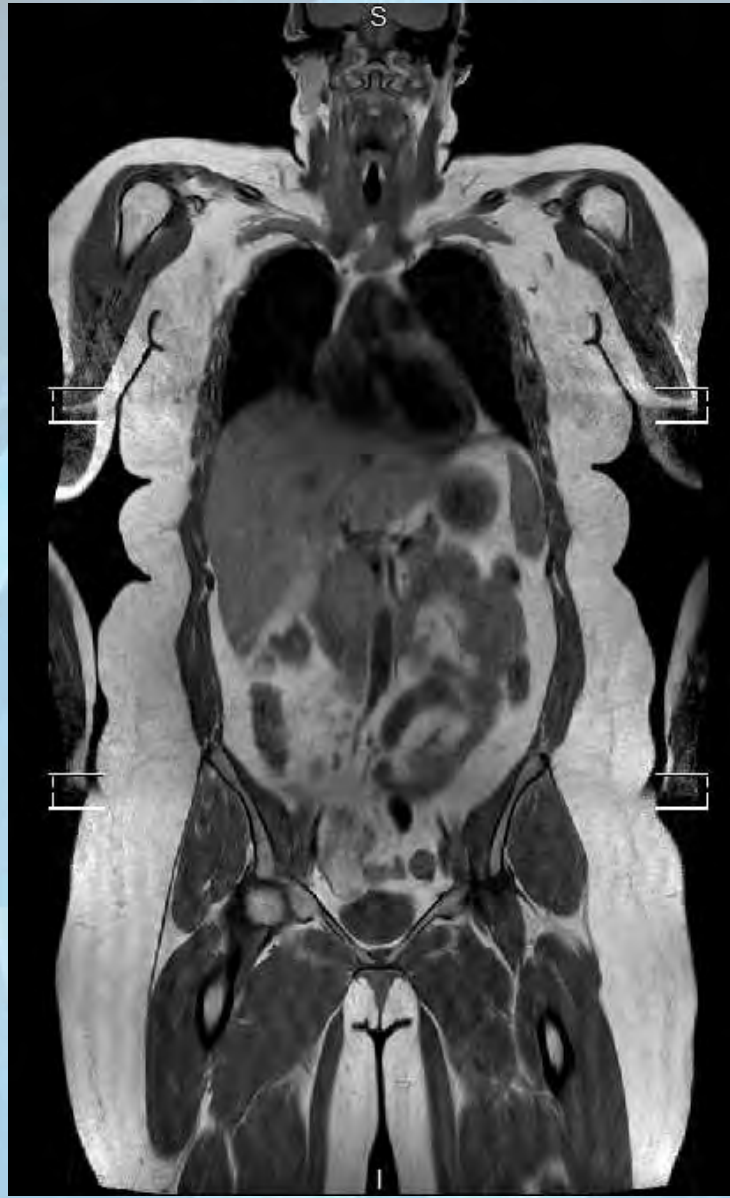
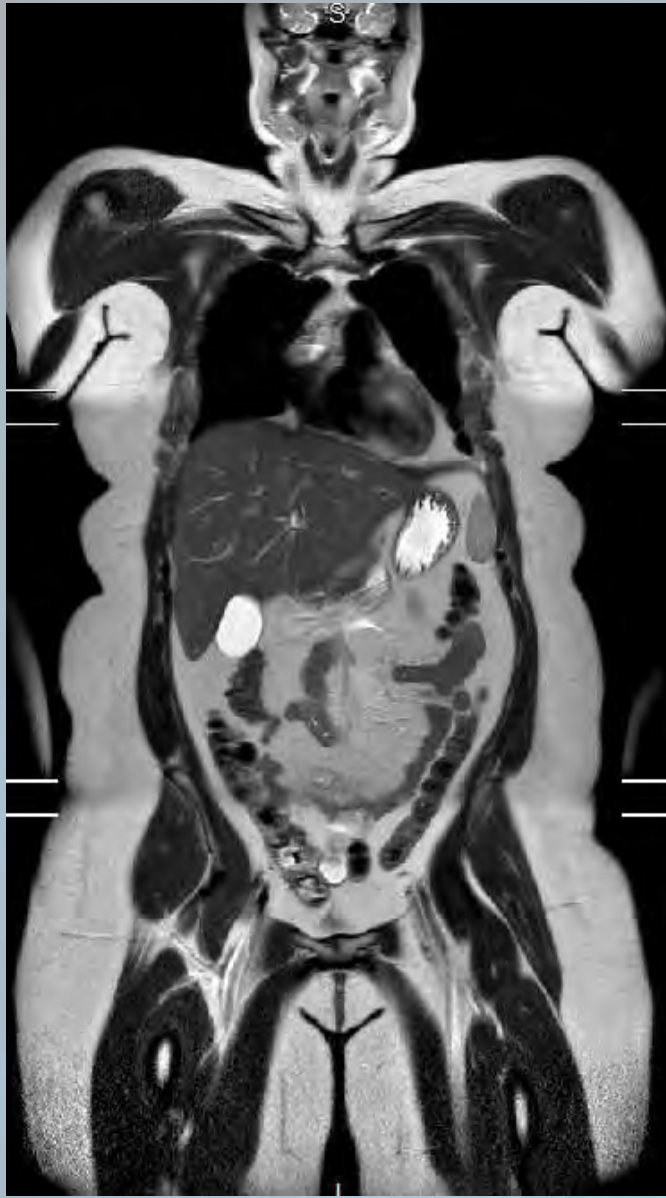- Read by MSK and Body radiologists

WHOLE-BODY SCREENING MRI: TECHNIQUE

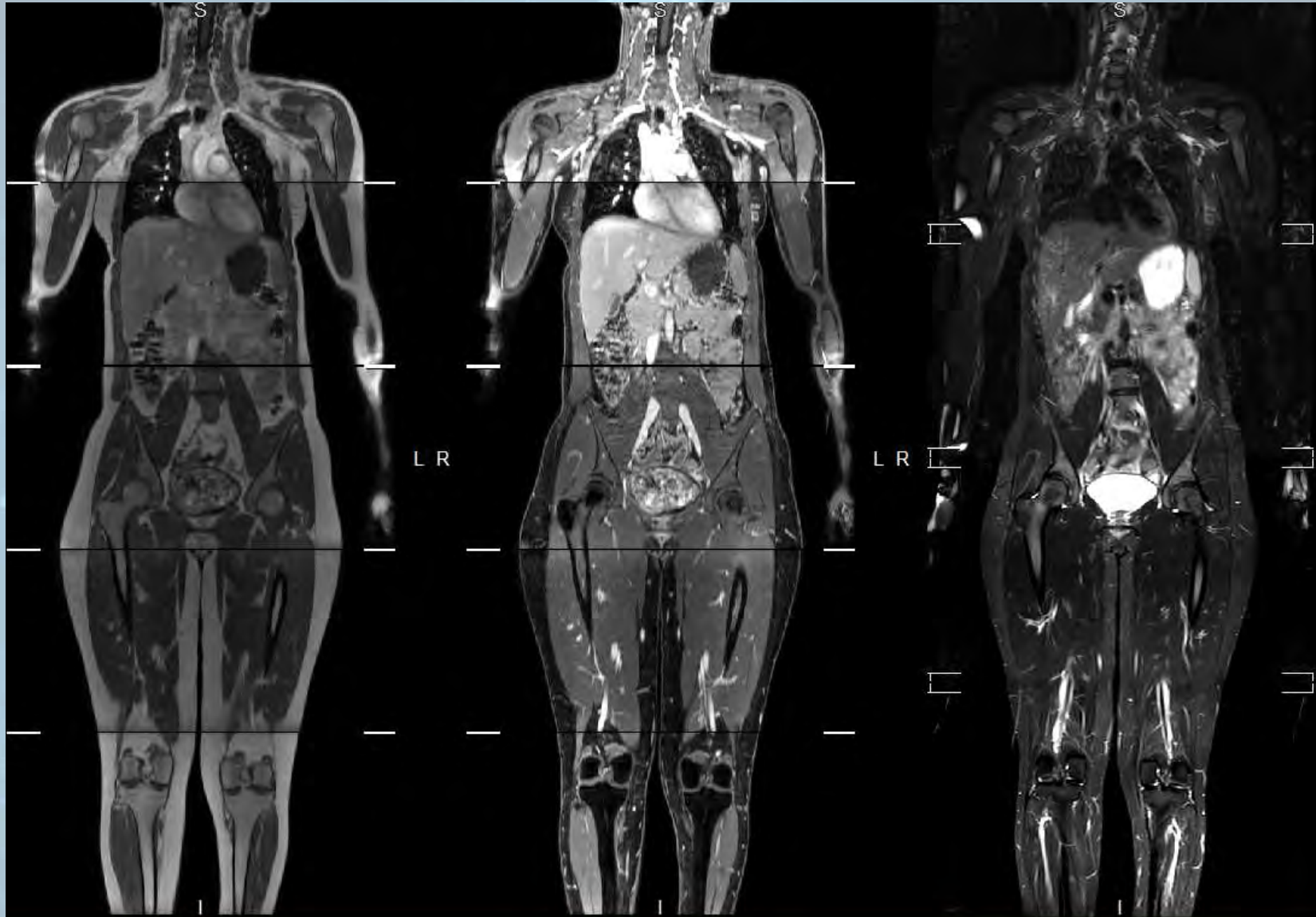
- Most without IV contrast
 - some with IV gadolinium if already had cancer
- Coverage - head/neck/chest/abd/pelvis +/- extremities
- 1 – 1.5 hours
- No solid food for 4 hrs, no liquids for 1 hr prior to exam
- Does not replace a dedicated screening breast MRI or a brain MRI with IV gadolinium
- Interpreted by MSK and Body radiologists
- If indeterminate findings are detected where cancer can not be excluded, may need additional imaging and/or biopsy

35 YO WOMAN WITH SDHx SYNDROME

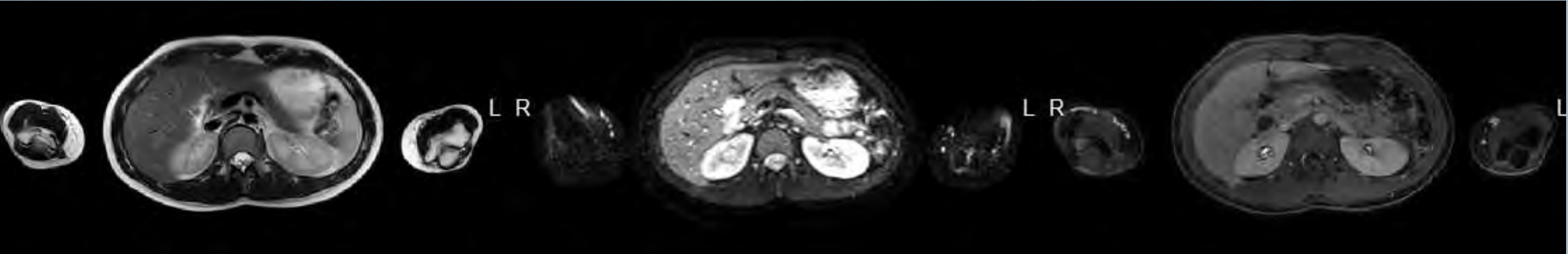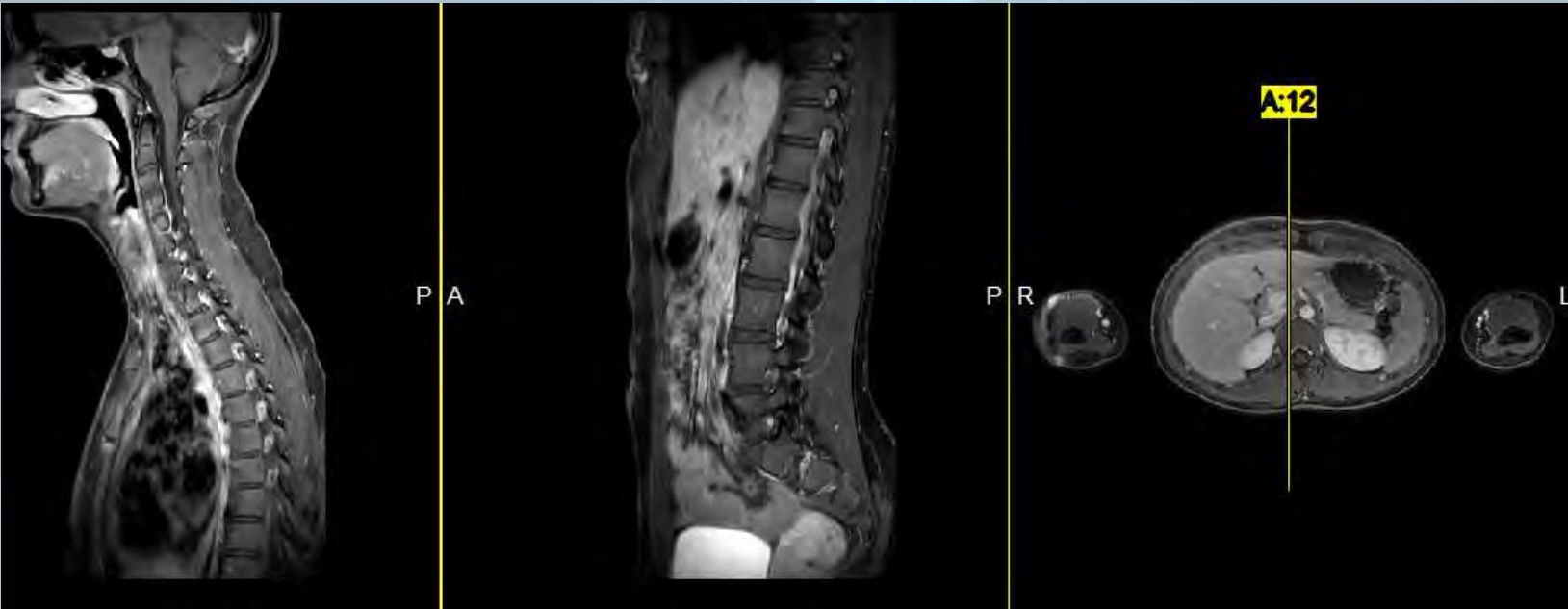




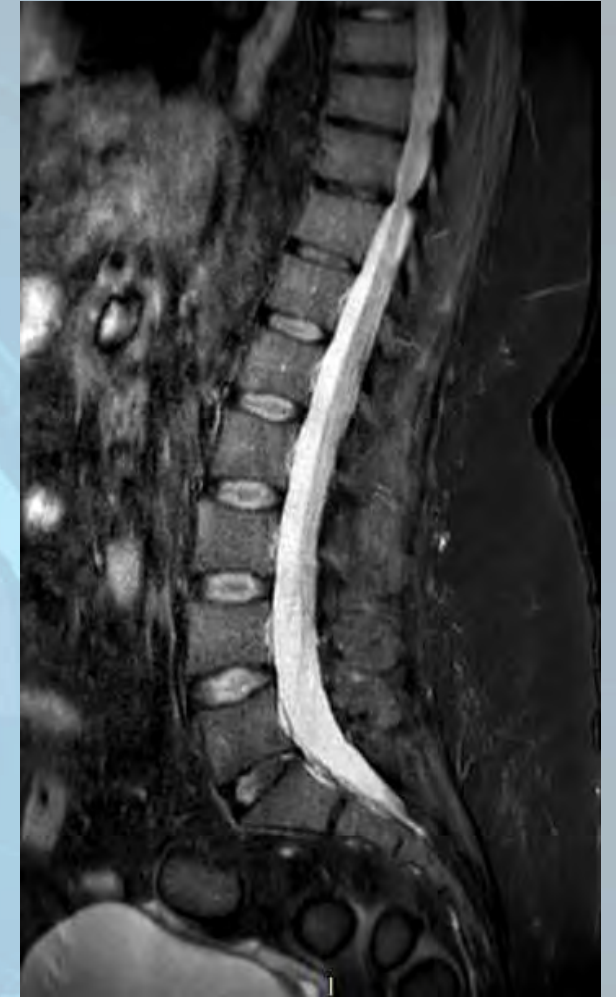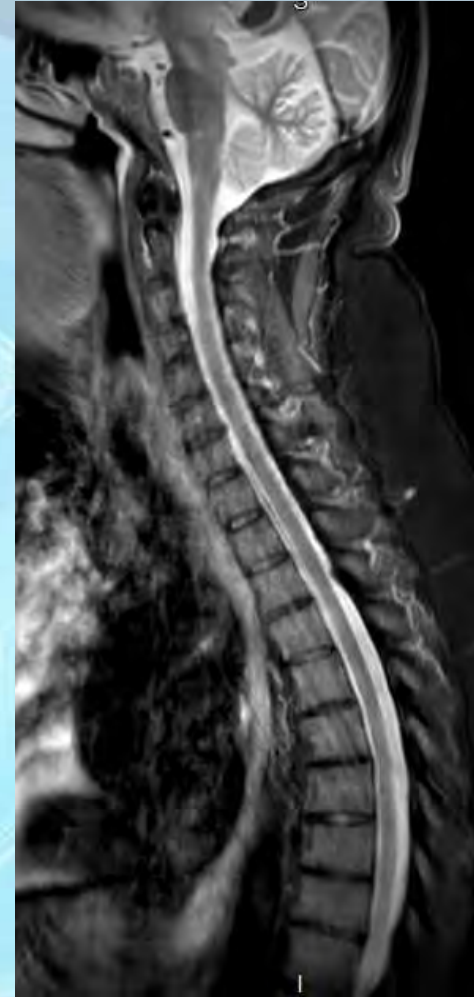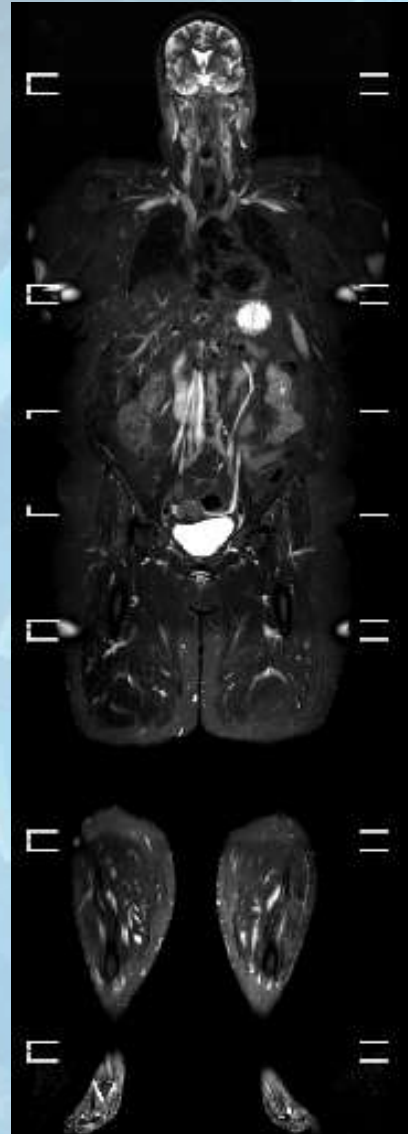
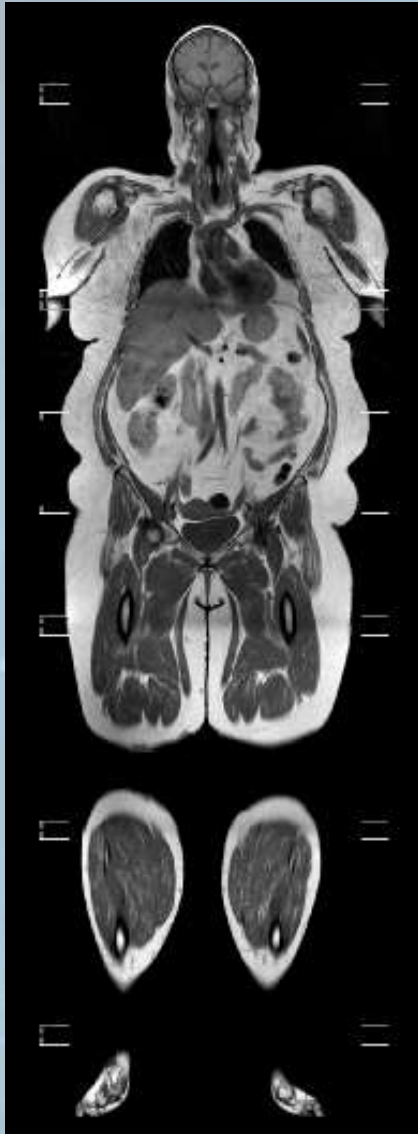
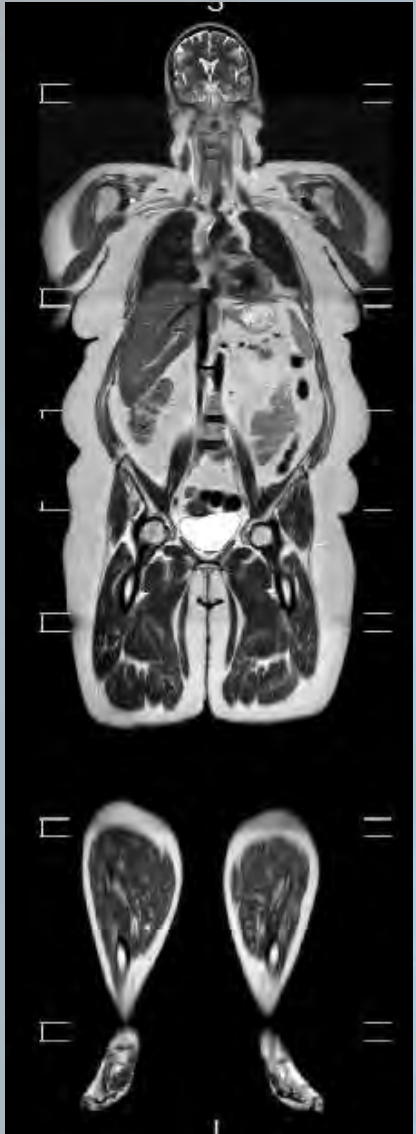17 yo girl with Li-Fraumeni syndrome, history of left calf rhabdomyosarcoma



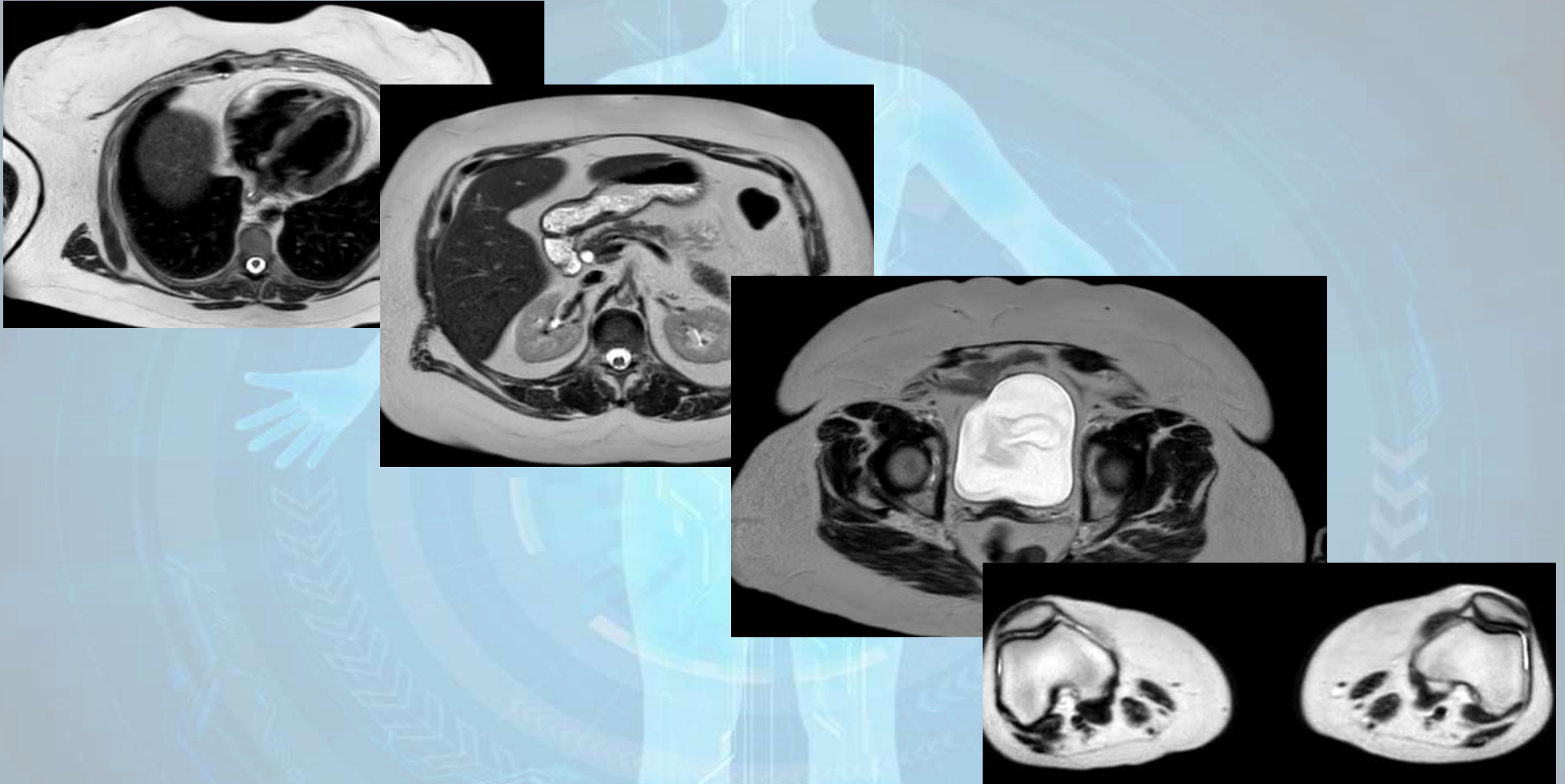
17 yo girl with Li-Fraumeni syndrome, history of left calf rhabdomyosarcoma



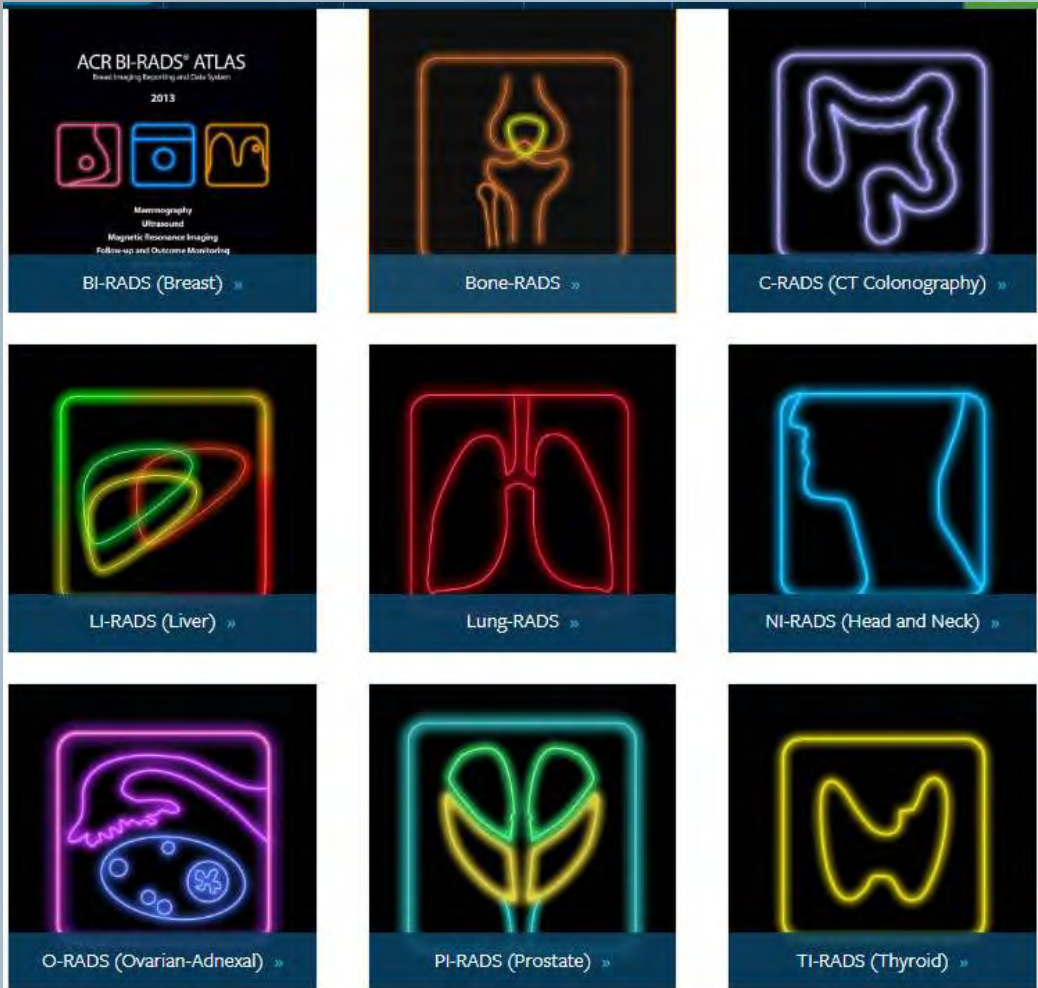RETINOBLASTOMA PROTOCOL: VERTEX TO TOE



RETINOBLASTOMA PROTOCOL: VERTEX TO TOE



WHOLE-BODY MRI REPORTING: ONCO-RADS?



Radiology

Latest Articles | Current Issue | All Issues | Collections ▾ | For Authors ▾ | Diagnosis Ple

Home > Radiology > Vol. 299, No. 3

NEXT >

Open Access

Reviews and Commentary
Review

Oncologically Relevant Findings Reporting and Data System (ONCO-RADS): Guidelines for the Acquisition, Interpretation, and Reporting of Whole-Body MRI for Cancer Screening

Giuseppe Petralia Dow-Mu Koh, Raj Attariwala, Joseph J. Busch, Ros Eeles, David Karow, Gladys G. Lo, Christina Messiou, Evis Sala, Hebert A. Vargas, Fabio Zugni, Anwar R. Padhani

▼ Author Affiliations

Published Online: Apr 27 2021 | <https://doi.org/10.1148/radiol.2021201740>

ONCO-RADS CLASSIFICATION

ONCO-RADS category for each abnormal finding

1	Normal
2	Benign finding highly likely
3	Benign finding likely
4	Malignant finding likely
5	Malignant finding highly likely
Other findings	Even if not suspicious for cancer, other findings should be included if considered important for an individual's health; anatomic variation should also be annotated

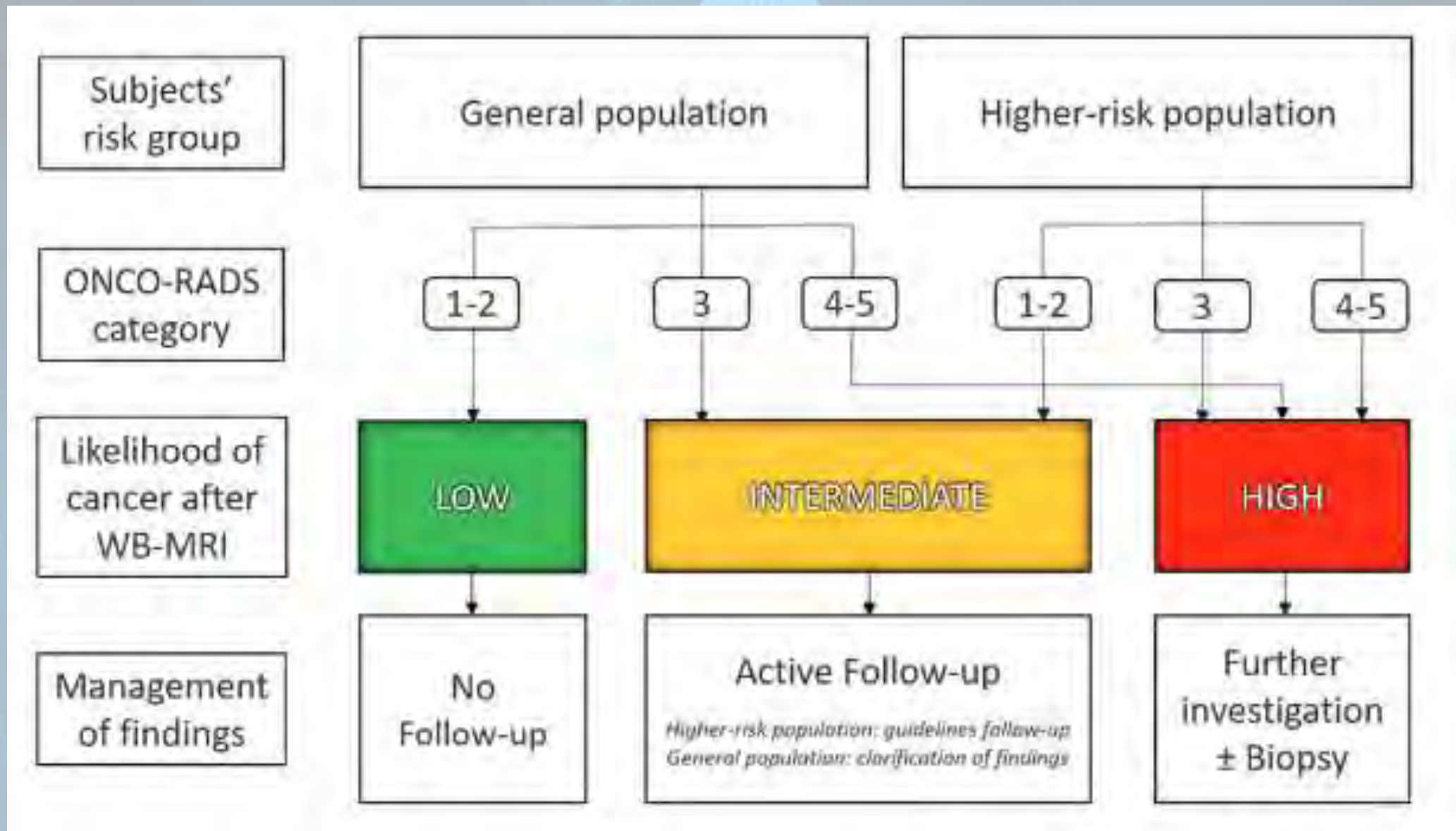


Table 4: Examples of the Most Frequently Observed Abnormal Findings in the Head, Neck, and Chest

ONCO-RADS Category	Head	Neck	Chest
Category 1, normal finding	Normal	Normal	Normal
Category 2, benign finding highly likely	Diffuse white matter alterations, diffuse mucosal thickening of paranasal sinuses, pharynx and/or larynx, arachnoid cysts	Nonsuspicious thyroid nodule <1 cm (in individuals <35 y),* nonsuspicious thyroid nodule <1.5 cm (in individuals ≥35 y),* lipoma	Lung nodules <6 mm, [†] thymic hyperplasia, pericardial cysts, lipoma
Category 3, benign finding likely	Isolated white matter alterations, focal mucosal thickening of paranasal sinuses, pharynx and/or larynx	Nonsuspicious thyroid nodule ≥1 cm (in individuals <35 y),* nonsuspicious thyroid nodule ≥1.5 cm (in individuals ≥35 y)*	Lung nodules 6–8 mm, [†] pneumonia, pleural effusion
Category 4, malignant finding likely	Brain lesion(s) suspicious for cancer (primary or metastatic)	Thyroid nodule(s) (solid), salivary gland solid lesion	Lung nodules >8 mm, mediastinal mass
Category 5, malignant finding highly likely	Brain lesion(s) with aggressive features, very suspicious for cancer (primary or metastatic)	Thyroid nodule(s) with aggressive features, very suspicious for cancer	Lesions with aggressive features, very suspicious for cancer, to lung, mediastinum
Other findings, including anatomic variations	Hydrocephalus, hemorrhage, cavum septum pellucidum, cavum vergae, mega cisterna magna, Chiari malformations	Thyroglossal duct cyst	Pneumothorax, thoracic aortic aneurysm, azygos lobe, thoracic aorta variants (eg, right-sided aortic arch, double aortic arch)

Note.—The threshold for assigning ONCO-RADS categories should be adapted to the individual's risk category (general population or higher risk including cancer predisposition syndromes). ONCO-RADS = Oncologically relevant findings Reporting and Data System.

* From reference 46.

[†] From reference 47.

Table 5: Examples of the Most Frequently Observed Abnormal Findings in the Abdomen and Pelvis

ONCO-RADS Category	Abdomen	Pelvis
Category 1, normal finding	Normal	Normal
Category 2, benign finding highly likely	Hemangioma (liver and spleen), cyst and hemorrhagic cyst <30 mm (kidney),* angiomyolipoma (kidney), adenoma (adrenal gland), steatosis (liver), lithiasis (gallbladder), lipoma	Benign prostatic hyperplasia (prostate), simple adnexal cyst ≤3 cm (postmenopausal), [†] simple adnexal cyst ≤5 cm (premenopausal), hemorrhagic adnexal cyst ≤5 cm (premenopausal), [‡] ovarian fibroid, [‡] uterine leiomyoma, para-ovarian cyst, luteal body
Category 3, benign finding likely	Solitary liver nodule ≥10 mm, solid likely focal nodular hyperplasia or adenoma, complex cyst (kidney), hemorrhagic cyst >30 mm (kidney),* pancreatic cyst ≤2.5 cm [‡]	Thickening of colorectal wall, simple adnexal cyst >3 cm (postmenopausal), [†] simple adnexal cyst >5 cm (premenopausal), [‡] hemorrhagic adnexal cyst (postmenopausal), [‡] hemorrhagic adnexal cyst >5 cm (premenopausal) [‡]
Category 4, malignant finding likely	Lesion(s) suspicious for cancer in liver (solid nodules), kidney (solid lesion or cystic lesion with solid component),* pancreatic cyst with worrisome features (≥3 cm, thick wall, mural nodule, main pancreatic duct >7 mm) [‡]	Lesion(s) suspicious for cancer to uterus (eg, focal endometrial thickening), prostate (impeded diffusion and hypointensity on T2-weighted image in the peripheral zone), colon and rectum, simple adnexal cyst ≥10 cm, adnexal cyst with solid tissue, thick irregular septa, papillary projections, locules with different signal intensity [‡]
Category 5, malignant finding highly likely	Lesion(s) with aggressive features in liver, kidney, pancreas, pancreatic cyst with high-risk features (solid component within the cyst, main pancreatic duct >10 mm, common bile duct dilatation) [‡]	Lesion(s) with aggressive features, very suspicious for cancer, to uterus, ovary, prostate, colon and rectum
Other findings, including anatomic variations	Abdominal aortic aneurysm, pancreas divisum, annular pancreas accessory spleen, inferior vena cava variants (persistent right posterior cardinal vein, persistent left supracardinal vein, retro-aortic left renal vein)	Fluid collection, uterine duplication anomalies (eg, uterus didelphys, bicornuate uterus septate uterus)

Note.—The threshold for assigning ONCO-RADS categories should be adapted to the individual's risk category (general population or higher risk including cancer predisposition syndromes). ONCO-RADS = Oncologically Relevant Findings Reporting and Data System.

* From reference 48.

[†] From reference 49.

[‡] From reference 50.

Table 6: Examples of Most Frequently Observed Abnormal Findings in the Bones and Limbs

ONCO-RADS Category	Bones	Limbs
Category 1, normal finding	Normal	Normal
Category 2, benign finding highly likely	Hemangioma, cyst, fat-poor bone marrow, bone island, enchondroma, healed fractures	Intramuscular hemangioma, lipoma
Category 3, benign finding likely	Bone lesion(s) with nonspecific features	Soft-tissue lesion(s) with unspecific features
Category 4, malignant finding likely	Bone lesion(s) suspicious for cancer (primary or metastatic)	Soft-tissue lesion(s) suspicious for cancer (primary or metastatic)
Category 5, malignant finding highly likely	Bone lesion(s) with aggressive features, very suspicious for cancer (primary or metastatic)	Lesion with aggressive features, very suspicious for cancer
Other findings, including anatomic variations	Fracture, transitional vertebrae (eg, lumbarization of S1, sacralization of L5)	Intramuscular hematoma

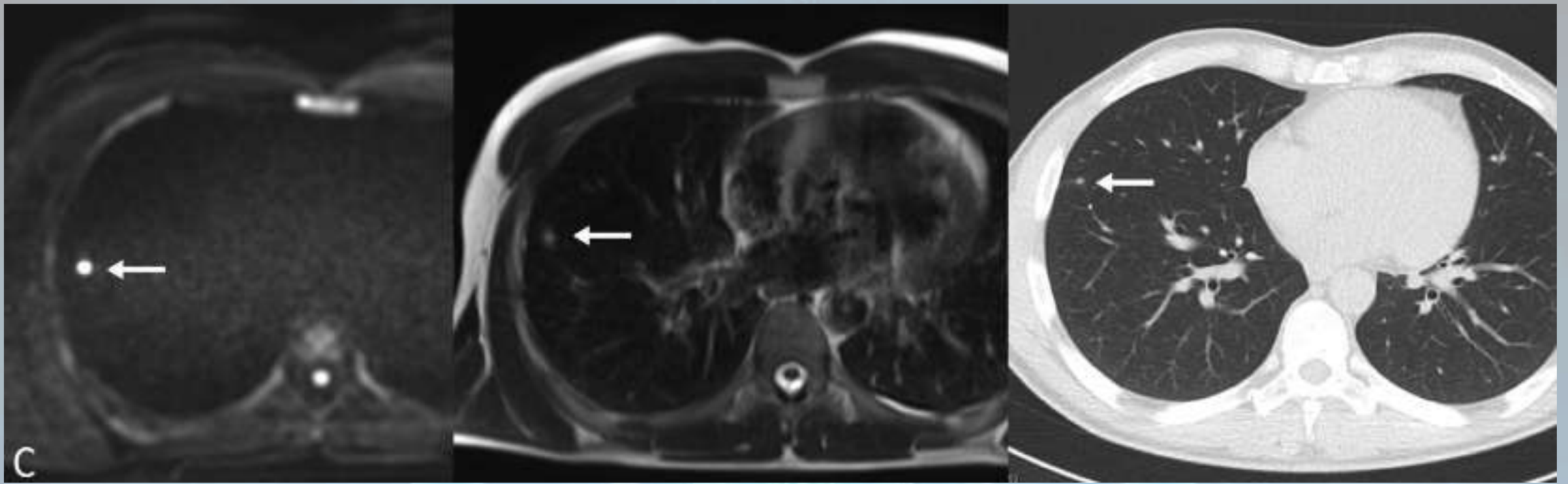
Note.—The threshold for assigning ONCO-RADS categories should be adapted to the individual's risk category (general population or higher risk including cancer predisposition syndromes). ONCO-RADS = Oncologically Relevant Findings Reporting and Data System.

Table 2: Examples of Possible False Findings for Cancer according to Anatomic Region

Region	False-Positive Findings	False-Negative Findings
Bones	Fractures, osteoarthritis, infection, bone infarcts, hemangiomas, enchondromas, ganglion cysts, focal red marrow, isolated bone marrow islands, artifacts around metal implants	Background bone marrow hypercellularity (due to young age, anemia or high-altitude living), sparse tumor cell infiltration pattern (eg, smoldering multiple myeloma), focal lesions with dense matrix mineralization, areas of body movement (eg, ribs and sternum), skull vault and base lesions
Head	Non-specific white matter signal changes, lymphoid tissue hypertrophy (eg, nasopharynx, oropharynx)	Small primary tumors and/or metastases within brain, small meningiomas, small primary tumors within nasopharynx and oropharynx
Neck	Reactive lymph nodes, nerve and ganglia, thyroid nodules	Thyroid cancers <1 cm, lesions arising in organs that normally show hyperintensity at diffusion imaging (eg, salivary glands, hypopharynx, and larynx)
Chest	Inflammatory lung nodules, reactive lymph nodes (eg, sarcoidosis), nerve and ganglia, proteinaceous breast cysts, breast fibroadenomas	Solid lung nodules <5 mm, pure ground-glass lung nodules <1 cm, small mediastinal lesions (due to cardiac and respiratory movement), nodal stations within the mediastinum and lung hilum, mucinous breast cancer, small breast cancers and in situ carcinomas
Abdomen	Hemangiomas, nerve and ganglia, reactive lymph nodes	Small lesions with unfavorable histomorphologic cell type (eg, clear cell renal cell carcinoma, tubulocystic renal cell carcinoma, hepatocellular carcinoma), metastases with mucinous deposits (eg, from mucinous colorectal carcinoma, mucinous ovarian cancer, and mucinous breast cancer) or with melanin rich deposits (eg, melanoma), lesions arising in organs that normally show hyperintensity at diffusion imaging (eg, spleen, adrenal glands, gastrointestinal wall)
Pelvis	Low flow and/or thrombosed varices, nerves and ganglia, reactive lymph nodes, gas artifacts to the bowel, adnexal masses	Lesions arising in organs that normally show hyperintensity at diffusion imaging (eg, testis, gastrointestinal wall), tumors with mucinous deposits (eg, mucinous colorectal carcinoma, mucinous ovarian cancer), small ovarian tumors
Limbs	Intramuscular hemangiomas, nerve, and ganglia, including neuromas, varices	Small soft-tissue sarcomas

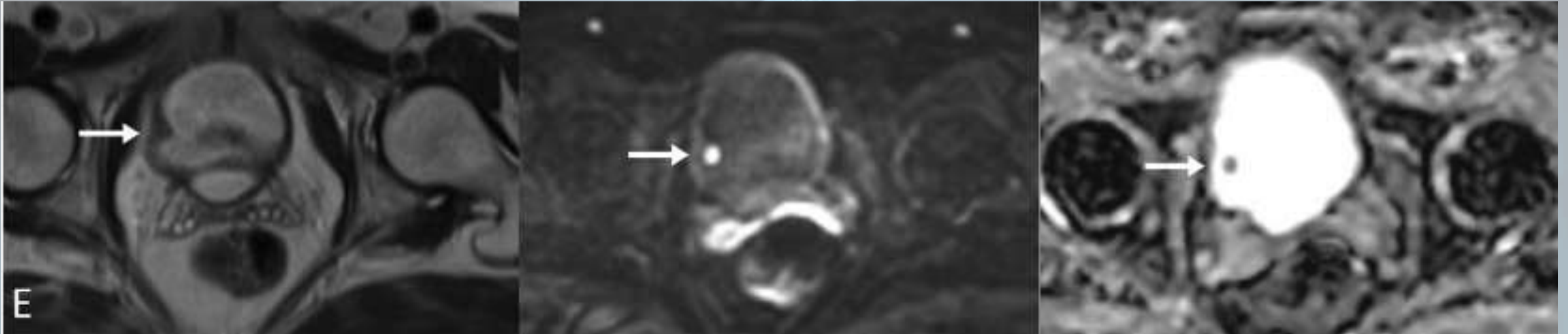
50-year-old man

- general population
- low prostate-specific antigen level (2.2 ng/mL)
- no other screening tests
- 15-mm incidental benign right adrenal adenoma
- ONCO-RADS category 2
- low likelihood of cancer
- no follow-up required



45-year-old man

- general population, no previous screening test
- hx of smoking and hypertension, family history of cancer (father, brother)
- 7 mm nodule in the right lower lobe of the lung on MRI
- ONCO-RADS category 3, intermediate likelihood of having cancer
- Chest CT at 6 months shows decreased size of lung nodule, consistent with benign nature



57-year-old man

- general population, negative fecal occult blood test, low PSA, no other screening tests
- heavy smoker, family history for urinary bladder cancer
- 8-mm right lateral bladder wall lesion, suspicious for bladder cancer, considered to have high likelihood of cancer
- transurethral resection showed noninvasive papillary carcinoma

ORDERING WHOLE-BODY MRI

- "MRI Whole Body Screening" - include gene mutation in "Indication"



MRI whole body screening

- "STIR Whole Body MRI" - include MSK indication or gene mutation in "Indication"



MRI stir whole body

ELECTIVE SCREENING WHOLE-BODY MRI IN GENERAL POPULATION

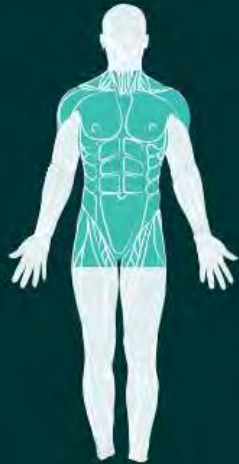- Commercially available
- No physician's order necessary
- No insurance coverage (most HSA/FSA eligible)
- Average \$1,000 – 5,000 (partial exams available based on desired anatomy)
- +/- consultation with a radiologist or a “health advisor”
- +/- communication with client's physician, online portal for results
- Most exams take 1 – 1.5 hrs to perform
- 1.5 or 3 Tesla MRI scanners, reasonable quality of images, interpreted by board-certified radiologists

APPROXIMATE COSTS FOR COMMERCIALLY AVAILABLE ELECTIVE SCREENING WHOLE-BODY MRI (GENERAL POPULATION)

Torso Scan

SCAN TIME: 20 MINUTES

Our quickest scan to search for cancer in the torso, not including the spine.



INCLUDES

- ✓ Solid organs of the chest, abdomen, and pelvis for solid tumors 1.5cm or larger
- ✓ Malignant cancer compared to benign conditions such as cysts, hematoma, hemangiomas, and abscesses
- ✓ Does not include a spine evaluation
- ✓ Does not include a detailed heart screening

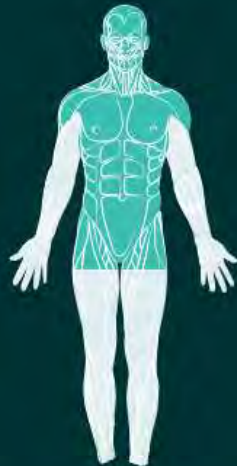\$999

SELECT SCAN

Head & Torso Scan

SCAN TIME: 45 MINUTES

A more detailed version of our Torso scan that includes a brain evaluation, not including the spine.



INCLUDES

- ✓ Solid organs of the chest, abdomen, and pelvis for solid tumors
- ✓ Higher detail that can detect tumors as small as 1cm
- ✓ Malignant cancer compared to benign conditions such as cysts, hematoma, hemangiomas, and abscesses
- ✓ Head and neck scan for brain and neck tumors (e.g. SCC, larynx, oral, tongue, parotid)
- ✓ Pelvis scan that is even more sensitive to smaller prostate, cervical, uterine, and ovarian cancer
- ✓ Potentially treatable brain aneurysms
- ✓ Does not include a detailed heart screening or spine evaluation

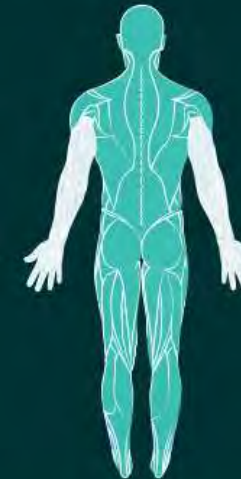\$1799

SELECT SCAN

Whole Body Scan

SCAN TIME: 60 MINUTES

Our most comprehensive scan that assesses your anatomy, including major organs and spine.



INCLUDES

- ✓ A complete Head & Torso Scan, with the addition of a spinal evaluation
- ✓ Disc herniation
- ✓ Spinal cord abnormalities
- ✓ Spinal degeneration
- ✓ Musculoskeletal conditions
- ✓ Fatty liver disease
- ✓ Hemochromatosis
- ✓ MS detection
- ✓ Does not include a detailed heart screening
- ✓ Ankle assessment included for people less than 5'9" or 175 cm tall

\$2499

SELECT SCAN

"NARROWING THE DISPARITY GAP"??

THE WALL STREET JOURNAL.

HEALTH | WELLNESS

**Wealthy People Are Getting Full-Body Scans. Early
Detection or Unnecessary?**

The real cost of a preventive health scan goes well beyond the price tag

WHY \$\$\$ ELECTIVE WHOLE-BODY SCREENING?

- General aging
- Peace of mind
- Genetic and family history of cancer
- **Anxiety**
- **Cancer treatment and remission**
- **Proactive health**
- Unexplained pain
- Lifestyle changes
- Somatic symptom disorder
- Illness anxiety disorder

CANCER DETECTION RATE IN ASYMPTOMATIC SUBJECTS/GENERAL POPULATION

Cancer detection

a) *Literature review*

On a per-subject basis, across eleven studies [37–39, 41–48], a total of 93 WB-MRI examinations out of 5233 were reported as positive for malignancy (1.8%). Notably however, in the 10 studies [37–42, 44, 46–48] that reported the number of confirmed malignant cancers, these were ultimately established in 41 out of 3692 examinations (1.1%) (Table 1).

Magnetic Resonance | [Published: 13 December 2012](#)

Psychosocial consequences and severity of disclosed incidental findings from whole-body MRI in a general population study

[Carsten Oliver Schmidt](#) , [Katrin Hegenscheid](#), [Pia Erdmann](#), [Thomas Kohlmann](#), [Martin Langanke](#), [Henry Völzke](#), [Ralf Puls](#), [Heinrich Assel](#), [Reiner Biffar](#) & [Hans Jürgen Grabe](#)

European Radiology **23**, 1343–1351 (2013) | [Cite this article](#)

PSYCHOSOCIAL CONSEQUENCES OF WB-MRI IN GENERAL POPULATION

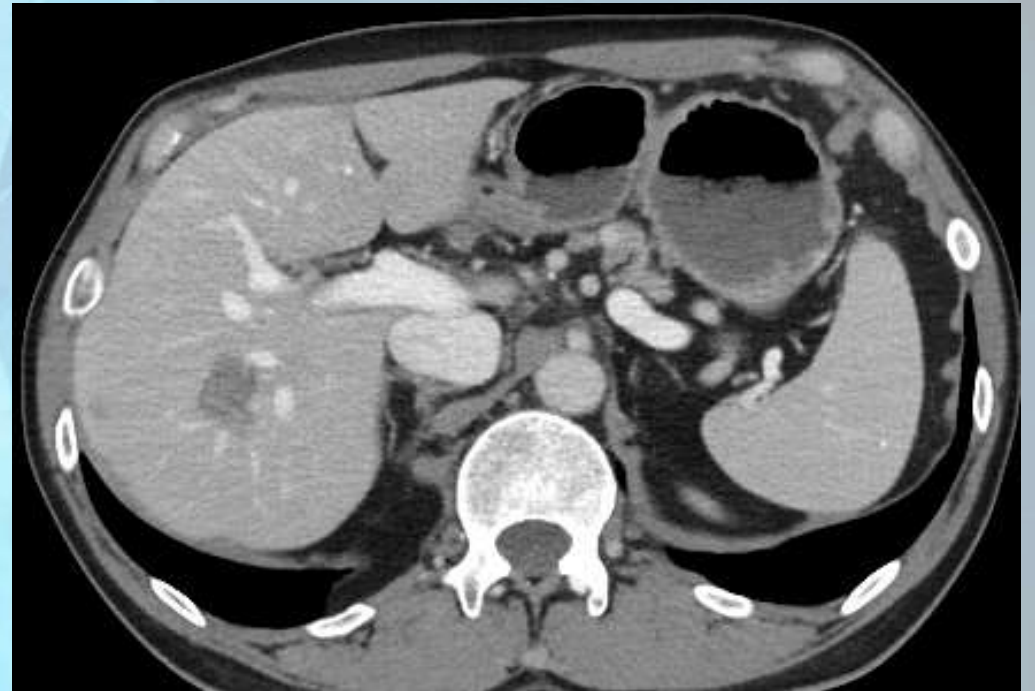- 9.9% reported strong distress while waiting for a potential notification of an incidental finding
 - “Scanxiety”, sleep disorder, psychological distress, uncertainty, depressed mood, social impairment, work disbalance, etc
- 28.6 % had moderate to severe psychological distress thereafter
- Strong disagreement between the subjective and radiological evaluation of the findings’ severity
- Almost all participants were very satisfied with their examination



SCREENING WHOLE BODY CT

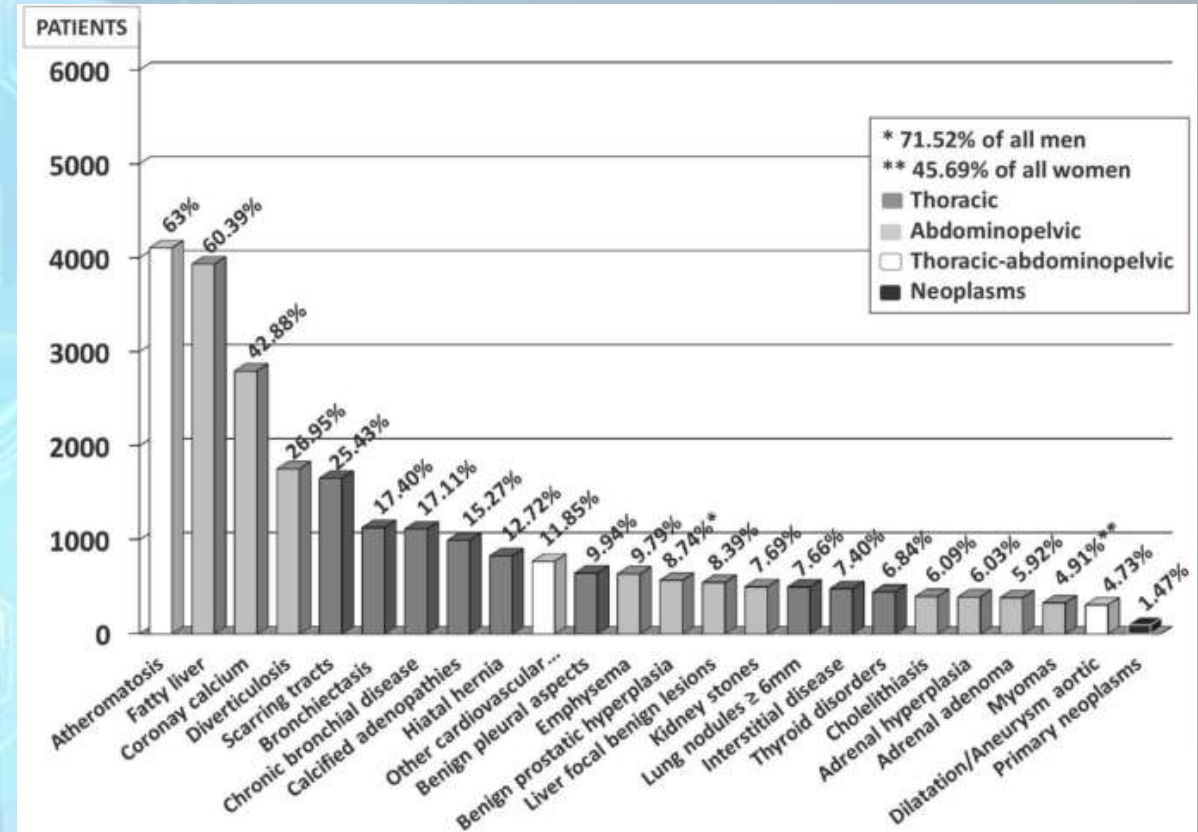
WHOLE-BODY CT FOR CANCER SCREENING

- Idea: CT can look inside and see cancers early
- Seems was most popular in US in early 2000s
- Most done without contrast
- Screening is not solely for cancer (CAD, AAA)



WHOLE-BODY CT - EVIDENCE

- Very little published
- 2008 study said 10% of radiologists read whole body screening CTs
- 2005 study: 1192 patients
 - 37% with recommended follow-up
 - No data on cancer detection
- 2019 study: 6516 patients in Spain
 - 1.5% cancer detection rate
 - Most common were renal and lung
 - 15.3 mSv radiation dose



WHOLE-BODY CT - RECOMMENDATIONS



- ACR: Does not believe there is sufficient evidence
- FDA: No Proven Benefits for Healthy People
- AAFP: Don't use whole-body scans for early tumor detection in asymptomatic patients

September 28, 2002

ACR Statement on Whole Body CT Screening

 Share  Recommend  Bookmark

(supersedes statement of Sept. 27, 2000)

The American College of Radiology (ACR) recognizes that an increasing number of computed tomography (CT) screening examinations are being performed in the United States. Much CT screening is targeted at specific diseases, such as lung scanning for cancer in current and former smokers, coronary artery calcium scoring as a predictor of cardiac events and CT colonography (virtual colonoscopy) for colon cancer. Early data suggest that these targeted examinations may be clinically valid. Large, prospective, multicenter trials are currently under way or in the planning phase to evaluate whether these screening exams reduce the rate of mortality.

The ACR, at this time, does not believe there is sufficient evidence to justify recommending total body CT screening for patients with no symptoms or a family history suggesting disease. To date, there is no evidence that total body CT screening is cost efficient or effective in prolonging life. In addition, the ACR is concerned that this procedure will lead to the discovery of numerous findings that will not ultimately affect patients' health but will result in unnecessary follow-up examinations and treatments and significant wasted expense.

The ACR will continue to monitor scientific studies concerning these procedures.

<https://www.acr.org/Advocacy-and-Economics/ACR-Position-Statements/Whole-Body-CT-Screening>

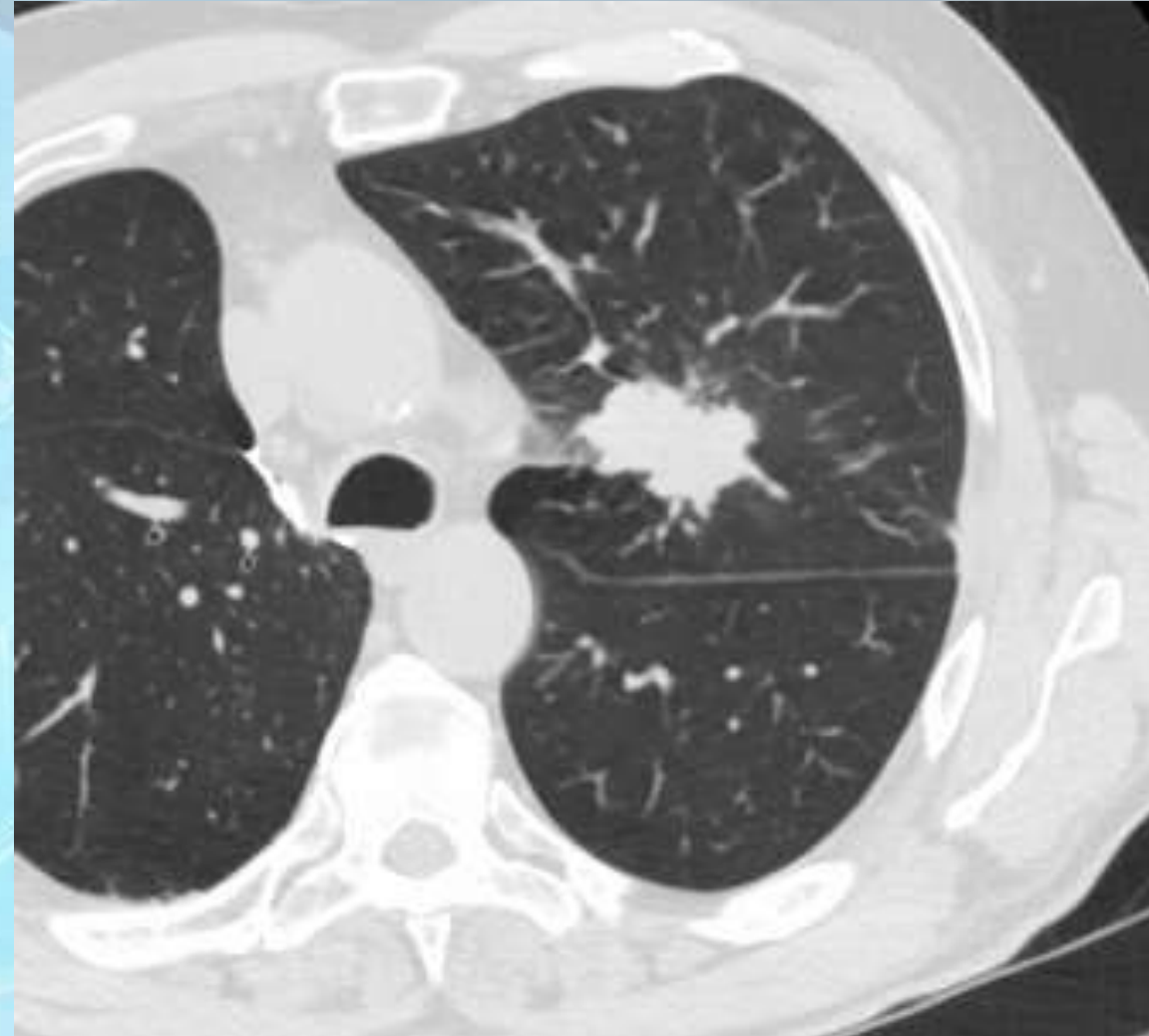Whole-Body CT Screening--Should I or shouldn't I get one?

In summary, when possible risks are compared to the possible benefits, the harms currently appear to be both far more likely and in some cases may not be insignificant. These harms are: (1) radiation exposure which has a small risk of cancer induction for an individual CT procedure, and (2) the possibility of either a false finding of an abnormality or a true finding of an insignificant abnormality, either of which could lead to further harm.

So, if you are apparently healthy, the good news is that the probability is already high that there is nothing seriously wrong with you, without your ever getting a whole-body CT screening exam.

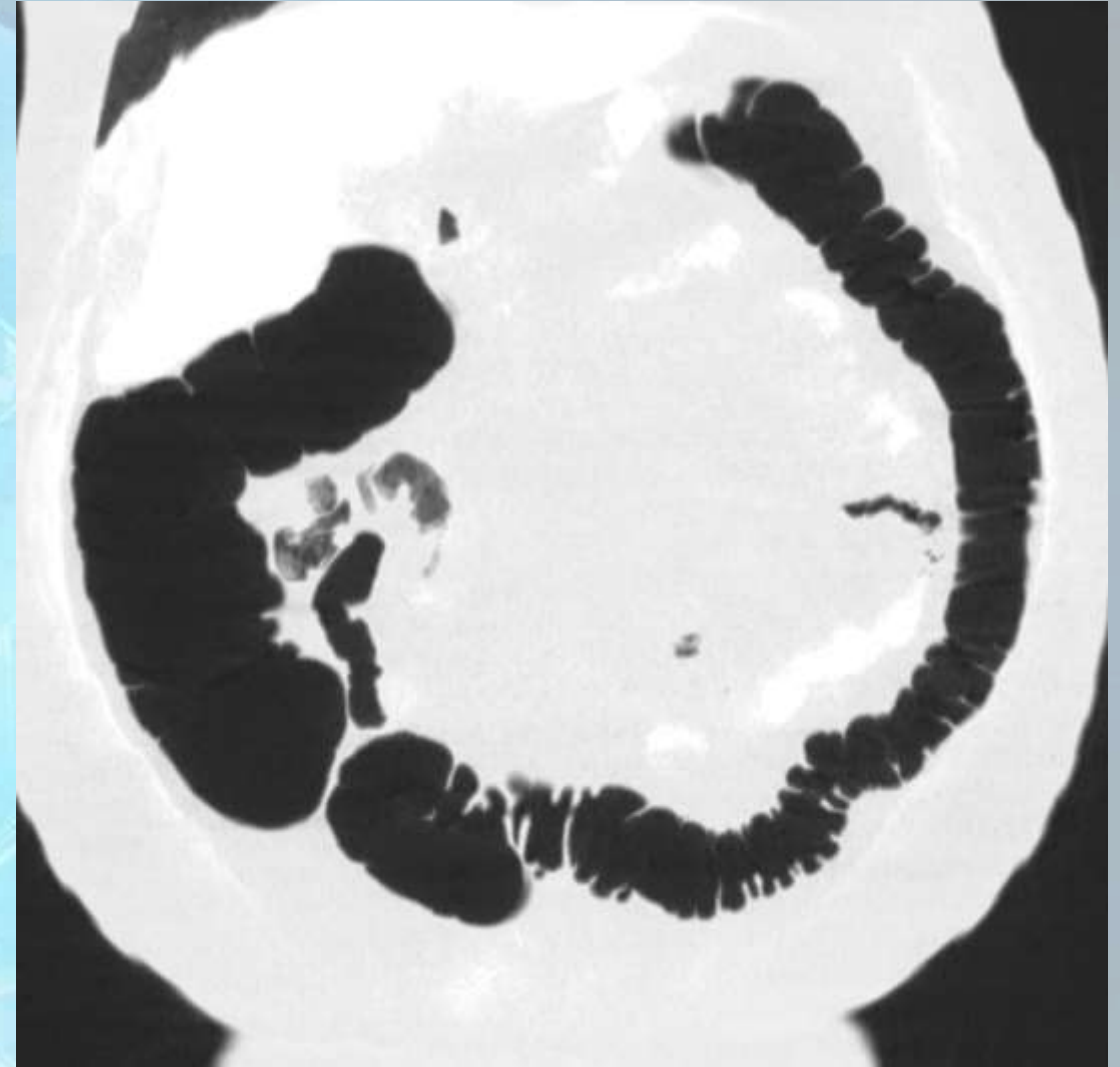
APPROPRIATE CT SCREENING - LUNG

- In patient with high risk
 - 50-80 years old
 - 20 pack year
 - Quit within 15 years
- Annual Low Dose, Non-contrast CT
- Both ACR and USPSTF recommend
- 2011 NLST – 20% reduction lung cancer mortality



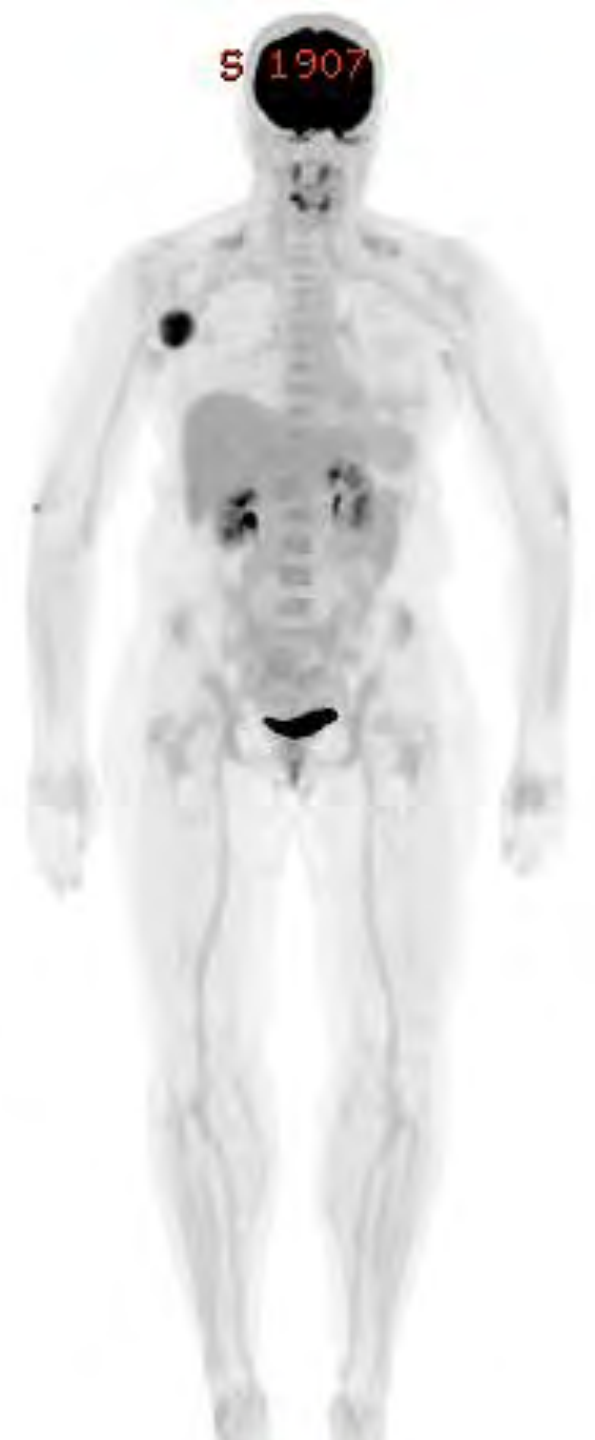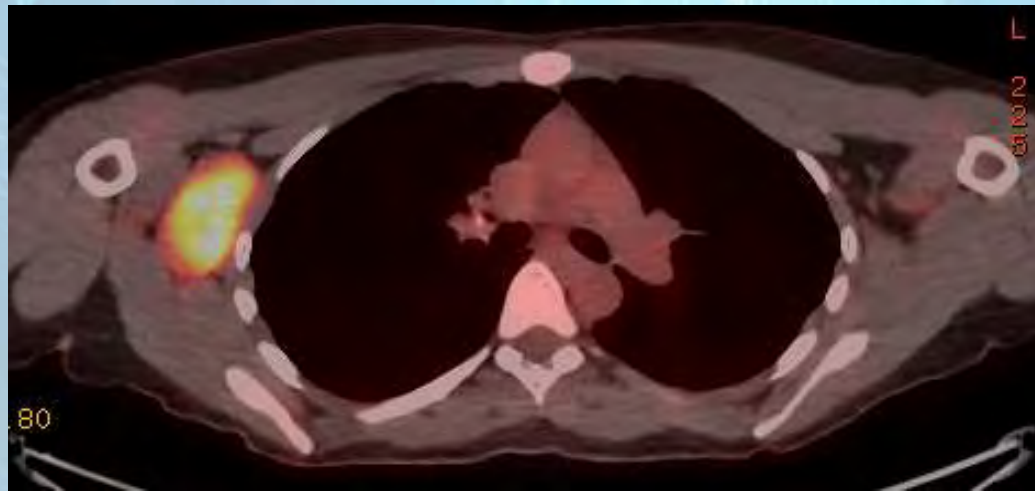
APPROPRIATE CT SCREENING - COLONOGRAPHY

- No Sedation, Lower perforation risk
- Radiation and incidentals
- Sens/Spec of 94/88 for >10mm Polyps
- 8% referral rate to colonoscopy
- ACR recommends >50 y/o, every 5yrs
- USPSTF – Insufficient evidence



WHOLE BODY PET/CT FOR SCREENING

- Many cancers have increased metabolism
- F-18 Fluorodeoxyglucose PET may therefore help find cancers
- When combined with CT, potential cancers can be found and acted on early
- Comes at cost of relatively high radiation



PET/CT SCREENING RECOMMENDATIONS

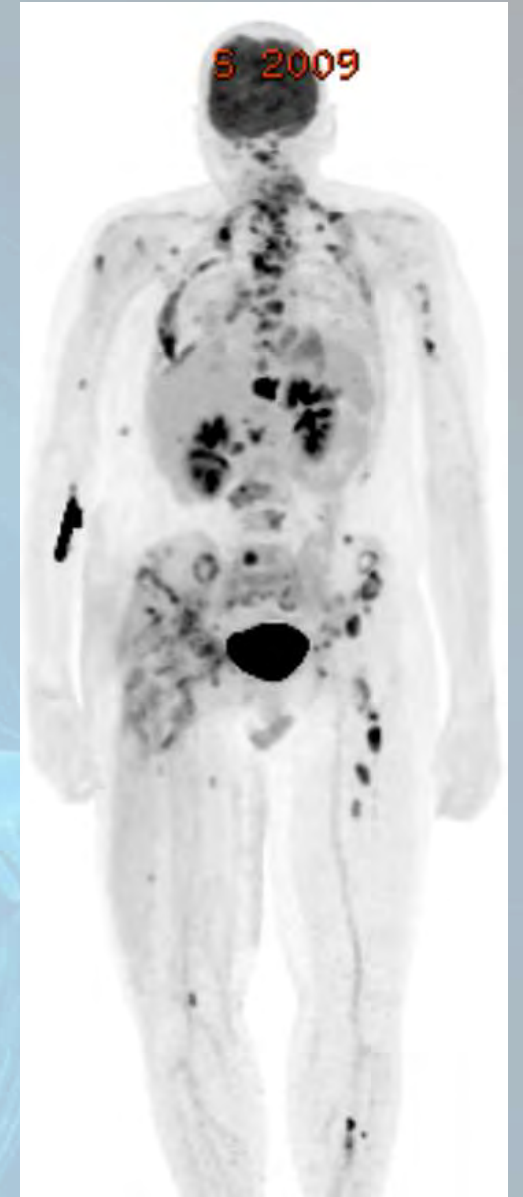
- ACR does not address whole body PET/CT for general screening
- Rated as “usually not appropriate” as screening for lung and breast cancers
- Not adequately studied
- Radiation Risk

Variant 1: Breast cancer screening. Average-risk women: women with <15% lifetime risk of breast cancer.

Procedure	Appropriateness Category	Relative Radiation Level
Mammography screening	Usually Appropriate	☼☼
Digital breast tomosynthesis screening	Usually Appropriate	☼☼
US breast	May Be Appropriate	○
MRI breast without and with IV contrast	Usually Not Appropriate	○
MRI breast without IV contrast	Usually Not Appropriate	○
FDG-PET breast dedicated	Usually Not Appropriate	☼☼☼☼
Sestamibi MBI	Usually Not Appropriate	☼☼☼

PET/CT SCREENING EVIDENCE

- Has been used for screening in Japan & Taiwan
- Most studies from 2000-2010
- Example Study: ~50,000 persons screened in 2005
- 9.8% had findings concerning for cancer
- 1.1% had cancers, 0.9% were PET positive
- Thyroid, Lung, Colon & Breast cancers were ~60% of cases
- PPV was 29%



Points to consider prior to whole-body screening

- Whole-body screening has not been demonstrated to meet generally accepted criteria for an effective screening procedure
- Medical professional societies have not endorsed whole-body screening scanning for individuals without symptoms
- The radiation from a CT scan may be associated with a very small increase in the possibility of developing cancer later in a person's life

WHOLE-BODY SCREENING EXAMS



PROS

- Whole-Body MRI
- No radiation
- May detect some tumors that otherwise would not be visible
- Relatively time efficient compared to multiple separate MRIs
- High sensitivity

CONS

- Potential for false positive results, which may lead to unnecessary tests and procedures
- Potential for false negative results
- Elective test if no clear indication
- Expensive, not covered by insurance
- Communication with clinical team regarding findings

REFERENCES

- <https://www.choosingwisely.org/patient-resources/whole-body-scans-to-screen-for-cancer/>
- <https://pubs.rsna.org/doi/full/10.1148/radiol.2021201740>
- <https://www.usatoday.com/story/entertainment/celebrities/2023/05/03/maria-menounos-pancreatic-cancer-brain-tumor-baby/70178359007/>
- Ladd SC. Whole-body MRI as a screening tool? Eur J Radiol. 2009;70(3):452-62.
- Schmidt G, Dinter D, Reiser MF, Schoenberg SO. The uses and limitations of whole-body magnetic resonance imaging. Dtsch Arztebl Int. 2010;107(22):383-9.
- Full-Body CT Scans – What You Need to Know, Radiation-Emitting Products. U.S. Department of Health and Human Services [Internet]. Silver Spring, MD: U.S. Food and Drug Administration; 2010 [updated 2010 Apr 6; cited 2014 Dec 5]. Available from: <http://www.fda.gov/Radiation-EmittingProducts/RadiationEmittingProductsandProcedures/MedicalImaging/MedicalX-Rays/ucm115340.htm>.
- [Whole-Body MRI Screening in Asymptomatic Subjects; Preliminary Experience and Long-Term Follow-Up Findings - PMC \(nih.gov\)](#)
- Petralia G, Zugni F, Summers PE, Colombo A, Pricolo P, Grazioli L, Colagrande S, Giovagnoni A, Padhani AR; Italian Working Group on Magnetic Resonance. Whole-body magnetic resonance imaging (WB-MRI) for cancer screening: recommendations for use. Radiol Med. 2021 Nov;126(11):1434-1450. doi: 10.1007/s11547-021-01392-2. Epub 2021 Aug 2. PMID: 34338948; PMCID: PMC8558201.
- https://www.ncbi.nlm.nih.gov/pmc/articles/PMC7216394/pdf/40644_2020_Article_315.pdf
- <https://link.springer.com/article/10.1007/s00330-012-2723-8>